

# Prolyl Endopeptidase-like Deficiency Associated with Growth Hormone Deficiency

✉ Laura Sayol-Torres<sup>1</sup>, ✉ Maria Irene Valenzuela<sup>2</sup>, ✉ Rosangela Tomasin<sup>3</sup>, ✉ Paula Fernández-Alvarez<sup>2</sup>, ✉ Maria Clemente<sup>3</sup>, ✉ Diego Yeste<sup>3</sup>

<sup>1</sup>Hospital Universitari Vall d'Hebron, Department of Pediatrics, Barcelona, Spain

<sup>2</sup>Hospital Universitari Vall d'Hebron, Department of Molecular and Clinical Genetics, Barcelona, Spain

<sup>3</sup>Hospital Universitari Vall d'Hebron, Department of Pediatric Endocrinology, Barcelona, Spain

## What is already known on this topic?

Prolyl endopeptidase-like (PREPL) deficiency (MIM#616224) is a rare congenital disorder characterized by neonatal hypotonia and feeding difficulties, growth hormone (GH) deficiency and hypergonadotropic hypogonadism. This syndrome is an autosomal recessive disease resulting from mutations in the *PREPL* gene (MIM#609557).

## What this study adds?

This report describes a novel previously undescribed mutation in *PREPL*. We also describe a typical presentation of the syndrome, with early growth impairment in infancy due to GH deficiency and a good response to GH treatment. The description of new patients with PREPL deficiency syndrome is essential to better delineate the phenotypic and genotypic spectrum of the disease.

## Abstract

Prolyl endopeptidase-like (PREPL) deficiency (MIM#616224) is a rare congenital disorder characterised by neonatal hypotonia and feeding difficulties, growth hormone (GH) deficiency and hypergonadotropic hypogonadism. This syndrome is an autosomal recessive disease resulting from mutations in the *PREPL* gene (MIM#609557). Herein we report a 7-year-old female patient with biallelic mutations in *PREPL* (c.1528C>T in one allele and whole gene deletion in the other) with early growth impairment in infancy. GH deficiency was confirmed at 20 months of life. Recombinant GH treatment was introduced with a good response. Her clinical features were similar to those of previously reported cases. The description of new patients with PREPL deficiency syndrome is essential to better delineate the phenotypic and genotypic spectrum of the disease.

**Keywords:** Prolyl endopeptidase-like, growth hormone deficiency, genetics

## Introduction

The prolyl endopeptidase-like gene (*PREPL*) is ~43 kb long, located in 2p21 and encodes the PREPL protein which is a cytoplasmatic serine hydrolase belonging structurally to an oligopeptidase family (1). Historically PREPL deficiency was described as part of a recessive contiguous gene deletion syndrome involving *PREPL* and *SLC3A1*, known as hypotonia cystinuria syndrome (HCS). While cystinuria in

HCS is caused by *SLC3A1* deficiency, the other symptoms (neonatal hypotonia, growth impairment and cognitive problems) arise from PREPL deficiency (2). This second isolated PREPL deficiency is also known as congenital myasthenic syndrome 22 (MIM#616224).

To date, only fourteen mutations have been described in the *PREPL* gene that are associated with HCS or congenital myasthenic syndrome (3). Here we report a female child with isolated PREPL deficiency, with a single nucleotide



**Address for Correspondence:** Laura Sayol-Torres MD, Hospital Universitari Vall d'Hebron, Department of Pediatrics, Barcelona, Spain  
**Phone:** +34649380894 **E-mail:** laurasayol@gmail.com **ORCID:** orcid.org/0000-0001-9938-3256

**Conflict of interest:** None declared  
**Received:** 04.06.2021  
**Accepted:** 10.09.2021

©Copyright 2023 by Turkish Society for Pediatric Endocrinology and Diabetes  
The Journal of Clinical Research in Pediatric Endocrinology published by Galenos Publishing House.

variant (c.1528 C > T) in *PREPL* and a 0.031Mb deletion in 2p21 (including *PREPL* only).

Most of the available literature about *PREPL* deficiency focuses on neurological symptoms. In this report, we outline the hormonal disorders associated with this syndrome.

## Case Report

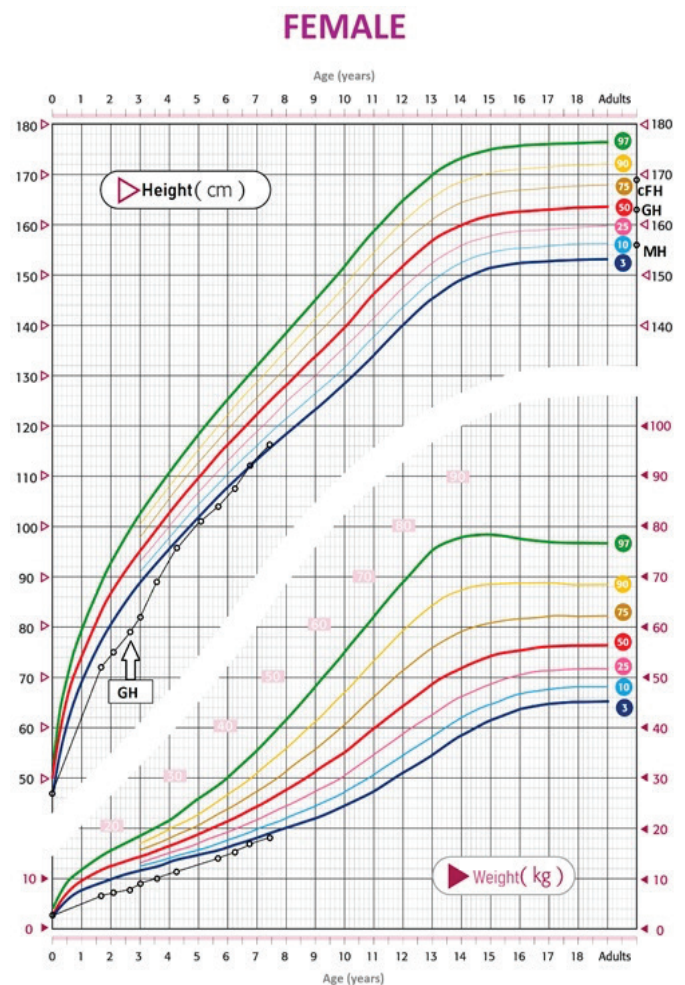
The proband is a 7-year-old female, born to nonconsanguineous caucasian healthy parents, with a healthy younger brother. Pregnancy was appropriately monitored and without major medical problems, teratogenic exposures or hospitalizations. The patient was born by C-section for breech presentation at 39 weeks of gestation. At birth, her weight was 2.855 g [-0.9 standard deviation (SD)], length 47 cm (-1.5 SD) and cranial perimeter 34.5 cm (+0.2 SD). Dysmorphic features were noted at birth, including broad nasal root, microretrognathia, mild thenar hypoplasia and bilateral 5<sup>th</sup> finger clinodactyly. She presented with neonatal hypotonia and was poorly reactive to stimulus. She suffered from neonatal hypoglycaemia due to feeding problems, so required a nasogastric tube for nutrition for the first month after birth. Among the diagnostic possibilities for the neonatal hypotonia, infection, cardiopathy and toxics were excluded. Additionally, she had a normal metabolic workup, no cystinuria and a normal electrocardiogram and brain magnetic resonance imaging (MRI) at birth. Electromyography at four months of age was also normal. Muscle biopsy was not performed, but levels of creatine-kinase were normal. Thyroid hormones were also normal. Thus, having ruled out other causes, array-CGH and also MLPA for Prader-Willi syndrome were performed with neither revealing any alterations.

Neurological evaluation at five months revealed persistence of global hypotonia with axial dominance, with apparent improvement over time. She acquired autonomous standing at one year of life and began autonomous ambulation at 18 months. She needed motor rehabilitation and stimulation in a specialized center.

Stunted growth became evident with a height of 72 cm (-3.8 SD) at 20 months of life. The serum insulin-like growth factor (IGF-1) level was low (27 ng/mL), as was the binding protein, IGFBP-3 level (1.78 mg/L). Pharmacological testing with glucagon showed no response, with the highest peak of growth hormone (GH) at the start (3.22 ng/mL) and only 0.48 ng/mL at 60 minutes. Additionally, she had a delayed bone age (9 months at a chronological age of 14 months). Celiac disease and hypothyroidism were excluded as part of the work-up for GH deficiency and a hypothalamic-hypophyseal MRI did not reveal any alteration. Being diagnosed with

GH deficiency, substitutive treatment was started at an age of 2 years and 8 months. She rapidly responded to GH treatment, significantly increasing growth velocity from 7 cm/year to 11 cm/year.

Currently, at 7 years and 5 months old, she is still under GH treatment with a good response (Figure 1), with a weight of 18 kg (-1.75 SD), a height of 116.5 cm (-1.8 SD) and a prepubertal Tanner staging (P1S1). Her bone-age is still younger than her chronological age. She eats all kinds of food in small quantities without dysphagia. On physical examination, she only presents left ptosis associated with fatigue, no hypomimia, and a normal axial tone. Dysmorphologic evaluation shows epicanthus, mandibular retrognathia, ogival palate, a notch in the earlobe and mild clinodactyly of the 5<sup>th</sup> finger with small but proportionate feet and hands. Ligament laxity is also evident. She has a nasal voice. Social development and educational attainment



**Figure 1.** Growth chart of our patient. The start of somatotropin treatment is indicated (GH), with a subsequent good response  
GH: growth hormone

are normal. Her motor exam revealed that the patient has a normal muscular axial tone and correctly aligned rachis, with normal osteotendinous reflexes and tendency to toe walking.

To identify the genetic condition of this patient, we first performed a next-generation sequencing study including genes *IGF2*, *IGF1R*, *IGF1*, *NPR2*, *GH1*, *GHR*, *GHRHR*, *IGFALS*, *STAT5B*, *CCDC8* and *GHSR* without revealing any pathogenic variant. Furthermore, methylation analysis of the Silver-Russell syndrome region was also normal. Therefore, whole-exome sequencing was carried out after obtaining informed consent from the patient's family. We identified an apparently homozygous variant in *PREPL* c.1528C>T, recognized as pathogenic in VarSome (4). The progenitor direct genetic study revealed that this was from paternal inheritance. Although the explanation for this apparently homozygous state could be an isodisomy, given that deletion of *PREPL* has been frequently described, an array-CGH (with exonic coverage of *PREPL*) was performed and it showed a 0.031Mb deletion in the 2p21 chromosome region (including the *PREPL* gene), classified as pathogenic with a recessive inheritance. The deletion was inherited from the mother. Therefore, the *PREPL* deficiency in the patient was due to a point mutation in one allele and a whole gene deletion in the other.

## Discussion

Hypotonia in early infancy may be a sign of a central nervous disorder, a primary neuromuscular disorder or a genetic syndrome associated with hypotonia. However these signs most frequently occur as a consequence of common neonatal conditions, such as congenital infections, hypothyroidism or drug toxicity. In the presented case, these more common conditions were excluded, so genetic syndromes were considered.

HCS has been described as a disorder with cystinuria and congenital myasthenia resulting from the recessive deletions in *SLC3A1* and *PREPL* (2,5,6,7,8). To date, only 11 patients (2,3,5,6,8,9) with isolated *PREPL* deficiency have been reported. Isolated *PREPL* deficiency causes an autosomal recessive inherited congenital myasthenic syndrome characterized by severe neonatal hypotonia that improves spontaneously with age, and endocrinology problems, such as GH hormone deficiency and hypergonadotropic hypogonadism. In late childhood (6-11 years) obesity can appear due to hyperphagia. Patients also show mild facial dysmorphism (9).

In this case, we found a novel heterozygous variant in c.1528C>T p.(Arg510Ter) in one allele associated with

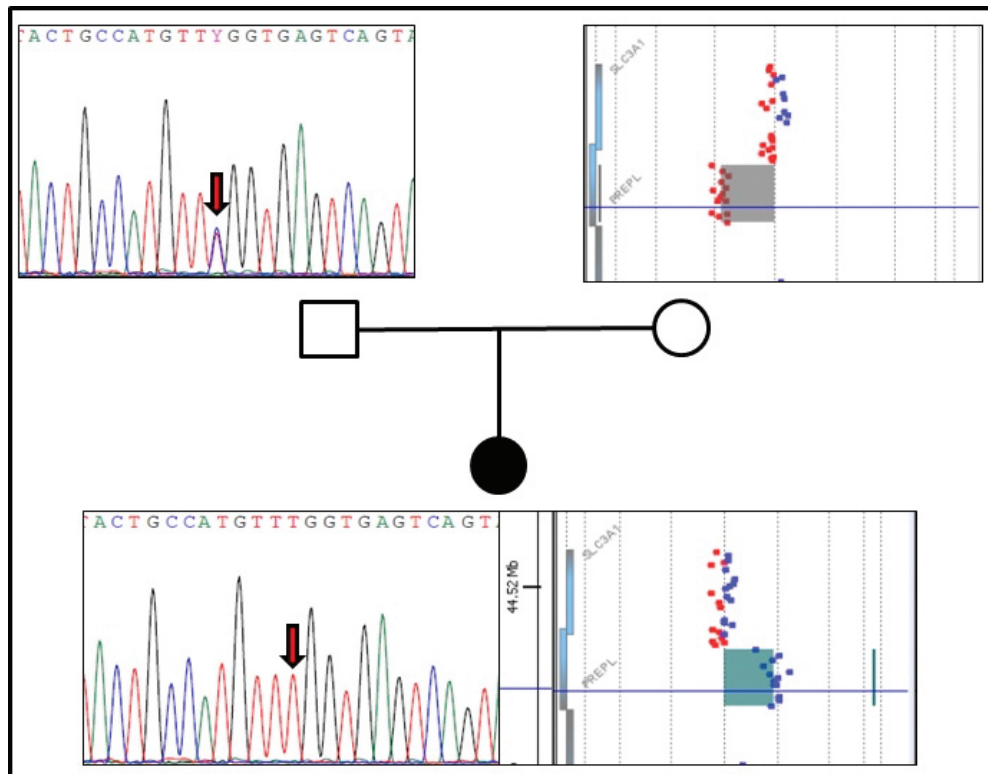
a whole gene deletion of 0.031Mb in 2p21 in the other. Further analysis showed that the novel mutation c.1528C>T p.(Arg510Ter), inherited from the father, results in a change of an arginine to a premature-stop-codon, resulting in a truncated protein or the absence of it, thus leading to a loss of function. This variant has not been identified previously in the public databases consulted (1000 genomes, exome variant server, exome aggregation consortium). The other variant, which was maternally inherited, was a 0.031Mb deletion in 2p21, implying a *PREPL* gene abnormality (Figure 2).

Patients with *PREPL* deficiency often present with growth deficiency and GH therapy has a positive effect in the cohort of cases that exhibit GH deficiency (2,5,6). In the presented case, the patient has received treatment with GH with a good response. However, the mechanism of GH deficiency associated with *PREPL* deficiency is unknown.

The *PREPL* gene is located in 2p21 and encodes the cytoplasmic *PREPL* protein which is ubiquitously expressed, with highest levels in brain, kidney, and skeletal muscle, in descending order (10). *PREPL* encodes a putative serine peptidase from the prolyl peptidase family (11). Prolyl peptidases cleave peptides on the C-terminal side of proline residues, modulating the levels of different peptides and hormones. Nonetheless, substrates for *PREPL* have not yet been identified and its exact cellular function remains unknown (1). Some clues might be found in the literature based on the function of its homologues *PREP* (prolyl oligopeptidase) and *OpdB* (oligopeptidase B) which suggest a proteolytic activity can be expected of *PREPL*. However, *PREPL* seems to have important cellular and physiological effects besides peptide cleavage, such as a role in growth cone development, acting as a binding partner of tubulin and influencing protein secretion, which are primarily due to protein-protein interactions (12).

Prolyl peptidases have the potential to participate in a wide range of cellular regulatory processes, as their substrates are involved in regulating different signalling pathways (13). Based on the clinical observation that patients with isolated *PREPL* deficiency exhibit GH deficiency, it has been hypothesized that *PREPL* might be involved in the secretion and/or processing of peptide hormones. It is possible that *PREPL* plays a role in signalling pathways, leading to, for instance, GH secretion. In addition, normal downstream signalling of the GH receptor is apparent from the reported good response of these patients to GH administration.

Patients with *PREPL* deficiency often develop obesity due to hyperphagia in late childhood but at the time of writing at an age of 7 years and 5 months, our patient has low intake and



**Figure 2.** Study of the genetic condition. Whole-exome sequencing identified an apparent homozygous variant in *PREPL* c.1528C > T from paternal inheritance. The array-CGH (with exonic coverage of *PREPL*) showed a 0.031Mb deletion in 2p21 chromosome (including *PREPL* gene) inherited from the mother. In the array-CGH, the DNA from the patient is signalled with CY3 red, whereas the DNA from the mother is signalled with CY5 blue

*PREPL*: prolyl endopeptidase-like gene

a normal body mass index (13.2 kg/m<sup>2</sup>; eighth percentile, -1.5 SD). Although hypergonadotropic hypogonadism has been observed in some patients with isolated *PREPL* deficiency (2), sexual hormones have not yet been tested in the proband because she has not reached a puberal age.

Previous studies (3,14) described moderate intellectual disability (ID) in *PREPL* deficient patients. Silva et al. (10) observed that biallelic *PREPL* mutations alone (without involvement of other genes) can cause ID. Besides the motor delay present in early infancy, the presented patient does not have developmental delay and has only needed some logopaedic therapy for diction problems. She also had the common phenotype associated with *PREPL* deficiency, including neonatal hypotonia and feeding problems during the first months after birth.

## Conclusion

Further follow-up of this patient is needed to report longer term outcomes and evaluate the response to GH treatment including the final height attained in adulthood.

## Ethics

**Informed Consent:** Consent form was filled out by the patient's family.

**Peer-review:** Externally peer-reviewed.

## Authorship Contributions

Surgical and Medical Practices: Laura Sayol-Torres, Maria Irene Valenzuela, Maria Clemente, Diego Yeste, Concept: Laura Sayol-Torres, Maria Irene Valenzuela, Rosangela Tomasini, Paula Fernández-Alvarez, Maria Clemente, Diego Yeste, Design: Maria Irene Valenzuela, Maria Clemente, Diego Yeste, Data Collection or Processing: Maria Clemente, Diego Yeste, Analysis or Interpretation: Maria Clemente, Diego Yeste, Literature Search: Maria Clemente, Diego Yeste, Writing: Laura Sayol-Torres, Maria Irene Valenzuela, Maria Clemente, Diego Yeste.

**Financial Disclosure:** The authors declared that this study received no financial support.

## References

1. Szeltner Z, Alshafee I, Juhász T, Parvari R, Polgár L. The PREPL A protein, a new member of the prolyl oligopeptidase family, lacking catalytic activity. *Cell Mol Life Sci* 2005;62:2376-2381.
2. Régál L, Mårtensson E, Maystadt I, Voermans N, Lederer D, Burlina A, Juan Fita MJ, Hoogeboom AJM, Olsson Engman M, Hollemans T, Schouten M, Meulemans S, Jonson T, François I, Gil Ortega D, Kamsteeg EJ, Creemers JWM. PREPL deficiency: delineation of the phenotype and development of a functional blood assay. *Genet Med* 2018;20:109-118. Epub 2017 Jul 20
3. Yang Q, Hua R, Qian J, Yi S, Shen F, Zhang Q, Li M, Yi S, Luo J, Fan X. PREPL Deficiency: A Homozygous Splice Site PREPL Mutation in a Patient With Congenital Myasthenic Syndrome and Absence of Ovaries and Hypoplasia of Uterus. *Front Genet* 2020;11:198.
4. Kopanos C, Tsiolkas V, Kouris A, Chapple CE, Albarca Aguilera M, Meyer R, Massouras A. VarSome: the human genomic variant search engine. *Bioinformatics* 2019;35:1978-1980.
5. Jaeken J, Martens K, Francois I, Eyskens F, Lecointre C, Derua R, Meulemans S, Slootstra JW, Waelkens E, de Zegher F, Creemers JW, Matthijs G. Deletion of PREPL, a gene encoding a putative serine oligopeptidase, in patients with hypotonia-cystinuria syndrome. *Am J Hum Genet* 2006;78:38-51. Epub 2005 Nov 23
6. Régál L, Shen XM, Selcen D, Verhille C, Meulemans S, Creemers JW, Engel AG. PREPL deficiency with or without cystinuria causes a novel myasthenic syndrome. *Neurology* 2014;82:1254-1260. Epub 2014 Mar 7
7. Legati A, Reyes A, Nasca A, Invernizzi F, Lamantea E, Tiranti V, Garavaglia B, Lamperti C, Ardisson A, Moroni I, Robinson A, Ghezzi D, Zeviani M. New genes and pathomechanisms in mitochondrial disorders unraveled by NGS technologies. *Biochim Biophys Acta* 2016;1857:1326-1335. Epub 2016 Mar 8
8. Tucker EJ, Jaillard S, Grover SR, van den Bergen J, Robevska G, Bell KM, Sadedin S, Hanna C, Dulon J, Touraine P, Sinclair AH. TP63-truncating variants cause isolated premature ovarian insufficiency. *Hum Mutat* 2019;40:886-892. Epub 2019 Mar 29
9. Laugwitz L, Redler S, Buchert R, Sturm M, Zeile I, Schara U, Wiczorek D, Haack T, Distelmaier F. Isolated PREPL deficiency associated with congenital myasthenic syndrome-22. *Klin Padiatr* 2018;230:281-283. Epub 2018 Jun 18
10. Silva S, Miyake N, Tapia C, Matsumoto N. The second point mutation in PREPL: a case report and literature review. *J Hum Genet* 2018;63:677-681. Epub 2018 Feb 26
11. Martens K, Derua R, Meulemans S, Waelkens E, Jaeken J, Matthijs G, Creemers JW. PREPL: a putative novel oligopeptidase propelled into the limelight. *Biol Chem* 2006;387:879-883.
12. Bartholdi D, Asadollahi R, Oneda B, Schmitt-Mechelke T, Tonella P, Baumer A, Rauch A. Further delineation of genotype-phenotype correlation in homozygous 2p21 deletion syndromes: first description of patients without cystinuria. *Am J Med Genet A* 2013;161:1853-1859. Epub 2013 Jun 21
13. Boonen K, Régál L, Jaeken J, Creemers JW. PREPL, a prolyl endopeptidase-like enzyme by name only?--Lessons from patients. *CNS Neurol Disord Drug Targets* 2011;10:355-360.
14. García-Horsman JA, Männistö PT, Venäläinen JI. On the role of prolyl oligopeptidase in health and disease. *Neuropeptides* 2007;41:1-24. Epub 2006 Dec 29