

Primary Thyroid Diffuse Large B-cell Lymphoma in a Child with Hashimoto's Thyroiditis: A Case Report

✉ Maria Xatzipsalti¹, ✉ Evangelos Bourousis¹, ✉ Maria Nikita², ✉ Dimitra Rontogianni³, ✉ Myrsini. G. Gkeli⁴, ✉ Dionisios Chrysis⁵, ✉ Aristeidis Giannakopoulos⁵, ✉ Dimitrios Delis¹, ✉ Margarita Baka², ✉ Andriani Vazeou¹

¹"P. & A. Kyriakou" Children's Hospital, A' Department of Pediatrics, Athens, Greece

²"P. & A. Kyriakou" Children's Hospital, Department of Oncology, Athens, Greece

³"Evangelismos" General Hospital, Department of Histopathology and Molecular Pathology, Athens, Greece

⁴Saint Savvas Anticancer Oncological Hospital of Athens, Department of Radiology, Unit of Sonography, Athens, Greece

⁵University of Patras Medical School, Department of Pediatrics, Division of Endocrinology, Patras, Greece

What is already known on this topic?

Primary thyroid diffuse large B-cell lymphoma (DLBCL) is extremely rare in children and an uncommon malignancy in adults. Hashimoto thyroiditis (HT) is a risk factor for DLBCL. Core needle biopsy is usually required for diagnosis.

What this study adds?

DLBCL should be considered in the differential diagnosis of a thyroid mass in adolescents with a history of HT. Diagnosis is difficult. Chemotherapy and/or radiology seems to be the most effective treatment, even in children. Surgical removal of the thyroid gland is limited to cases where chemotherapy fails.

Abstract

Primary thyroid lymphoma (PTL) is a rare thyroid gland cancer, with diffuse large B-cell lymphomas (DLBCL) being extremely rare in children and adolescents. Thus, optimal therapy is debatable. We describe a rare case of thyroid DLBCL in an adolescent girl with a history of Hashimoto thyroiditis (HT), the difficulty in diagnosis and the outcome of treatment. A 12-year-old girl with a nine-year history of HT was admitted with a right-sided painless progressive swelling of the neck. Physical examination and imaging including ultrasound (US), computed tomography (CT) and positron emission tomography/CT revealed an enlarged thyroid gland with right side lymphadenopathy and no metastasis. Two fine needle aspirations were done showing suspected lymphoblastic lesions for non-Hodgkin lymphoma without precise diagnosis. US guided core needle biopsy was finally performed confirming the diagnosis of DLBCL. She was treated according to LMB 96-group B protocol with no surgical removal of thyroid. The patient responded very well to treatment and 14 months later there is no evidence of relapse or metastases. PTL is an extremely rare cause of thyroid malignancy in children. However, it should be considered in the differential diagnosis of a thyroid mass in adolescents presenting with a rapidly enlarging neck mass and a history of HT. It is a treatable condition with a good prognosis, even in aggressive histological subtypes, with no need for thyroidectomy.

Keywords: Primary thyroid lymphoma, diffuse large B-cell lymphoma, children

Introduction

Studies in adults have shown that primary thyroid lymphoma (PTL) accounts for <5% of thyroid malignancies and <2% of extranodal lymphomas, with an annual estimated

incidence of 2 cases per 1 million. PTL is extremely rare in children, with only a few cases published (1). We describe a 12-year-old girl with Hashimoto thyroiditis (HT) and diffuse large B-cell lymphoma (DLBCL).



Address for Correspondence: Maria Xatzipsalti MD, "P. & A. Kyriakou" Children's Hospital, A' Department of Pediatrics, Athens, Greece
Phone: +30 213 200 98 55 **E-mail:** mxatzipsalti@yahoo.gr **ORCID:** orcid.org/0000-0001-8834-9642

Conflict of interest: None declared
Received: 22.05.2021
Accepted: 11.09.2021

©Copyright 2023 by Turkish Society for Pediatric Endocrinology and Diabetes
The Journal of Clinical Research in Pediatric Endocrinology published by Galenos Publishing House.

Case Report

A 12-year-old girl was referred to our department with a painless right sided enlargement of the neck, which was evident three weeks prior to presentation. There was a progressive deterioration, with no other symptoms. An ultrasound (US) elastography of the thyroid gland performed at that time showed a 3 cm hypoechoic solid nodule, with mild lobulated borders. That mass was highly suspicious of non-Hodgkin lymphoma (NHL), based on the fine needle aspiration biopsy (FNA) result, which was performed a few days before her presentation to us. However, no definite diagnosis could be made.

The patient's past medical history was remarkable for HT and she had been under treatment with levothyroxine, since

the age of two years (Table 1). There was a family history of thyroidopathy in her two older sisters. Her middle sister had HT since the age of 13 years and the eldest sister had thyroidectomy at the age of 23 years because of a thyroid nodule [classified according to the Bethesda System for Reporting Thyroid Cytopathology (TBSRTC)- category II-benign].

Physical examination revealed an enlarged thyroid gland with a notable soft mass (3 cm x 3 cm) on the right side of the thyroid and ipsilateral cervical lymphadenopathy. After admission, laboratory tests were performed. Full blood count, lactate dehydrogenase, and renal and liver function tests were all normal (Table 1). Her thyroid function tests are also shown in Table 1.

Table 1. Demographic, clinical and biochemical data of the patient

Age (years)	12 ^{9/12}	
Sex	Female	
Race	White Caucasian	
Past medical history	Hashimoto thyroiditis since 2 years of age	
Medical treatment	Thyroxine (1.2 µg/kg/d)	
Height	155 cm (50 th percentile)	
Weight	49 kg (50 th percentile)	
Body mass index	19.38 kg/m ² (25 th -50 th percentile)	
Tanner stage	5	
Blood tests		Reference range
Full blood count		
WBC	6200/µL (NE: 50.2%, LY: 41.1%, EO: 1.3%)	4.5-13.0x10 ³
Hb	11.1 gr/dL	11.5-15.5
HBC (MCV)	34% (78.3 fl)	35-45
Platelets	308000/µL	130-400x10 ³
ESR	5 mm/h	< 10
Biochemistry		
Urea	19 mg/dL	5-45
Creatinine	0.6 mg/dL	0.5-1
CRP	0 mg/dL	< 5
SGOT	11 U/L	5-45
SGPT	7 U/L	5-45
γGT	6 U/L	< 26
Lactate dehydrogenase	188 U/L	< 300
Hormones		
TSH	0.603 µIU/mL	0.4-5
FT4	1.37 ng/dL	0.9-1.9
T3	1.270 ng/dL	0.83-2.13
T4	8.15 µg/dL	5.6-13.9
Tg	69.94 ng/dL	3.5-31.1
Anti-TPO	278.7 IU/mL	< 16
Anti-TG	1287 IU/mL	< 100
Calcitonin	2.2 pg/mL	< 10

CRP: C-reactive protein, WBC: white blood cell, Hb: hemoglobin, HBC: hemoglobin C, MCV: mean corpuscular volume, ESR: erythrocyte sedimentation rate, EO: eosinophil, NE: neutrophil, LY: lymphocyte, TSH: thyroid stimulating hormone

A more detailed US examination of the thyroid gland was performed and showed an increase in the size, with a notable solid hypoechoic nodule (3.40 x 2.93 x 4.62 cm), with two jagged edges, lobulated borders, calcifications and intranodular vascularization on the right side of the gland. Furthermore, two hypoechoic nodules, smaller in size and with well-defined borders, and without internal vascularization were present on the left side of the gland. Multiple cervical lymph nodes were also found bilaterally. However, US was still non-diagnostic. A second FNA was performed, which showed suspicious lymphoblastic lesions. Due to the difficulty of making the diagnosis, a subsequent US-guided core needle biopsy (CNB) was carried out and confirmed the diagnosis (Figure 1) by histological examination.

Histopathological examination showed destruction of thyroid follicles and diffuse growth of lymphocytes (Figure 2a, 2b). Immunohistochemistry was positive for CD20 (Figure 3) with co-expression of PAX-5 transcription factor, and was positive for CD5, CD23, CD30, cyclinD and moderately positive for CD3. These markers are key immunohistochemical features for distinguishing between DLBCL and mucosa-associated lymphoid tissue (MALT)-derived subtypes. Antibody testing against antibody/proteins showed CD10 < 30%, bcl-6 < 30% and MUM-1/IRF4 > 30%. The Ki-67 index was 60%. Bcl-2 was positive in > 90% of the cell population examined. Fluorescence *in-situ* hybridization analysis revealed no translocation of the *MYC*, *BCL-2*, *DUSP22* and *IRF4* genes, indicating good prognosis (2).

Staging of the lymphoma included computed tomography (CT) scan of the neck, chest and abdomen, positron emission tomography/CT (PET/CT), bone marrow aspiration and cerebral spinal fluid (CSF) analysis. The CT scan of the

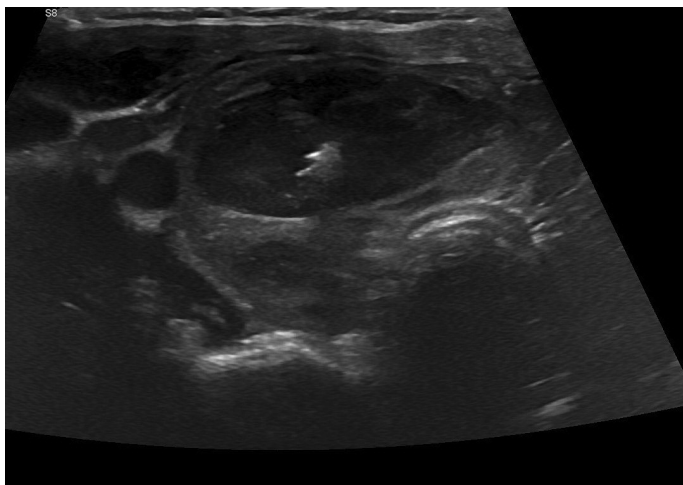


Figure 1. Ultrasound guided core needle biopsy

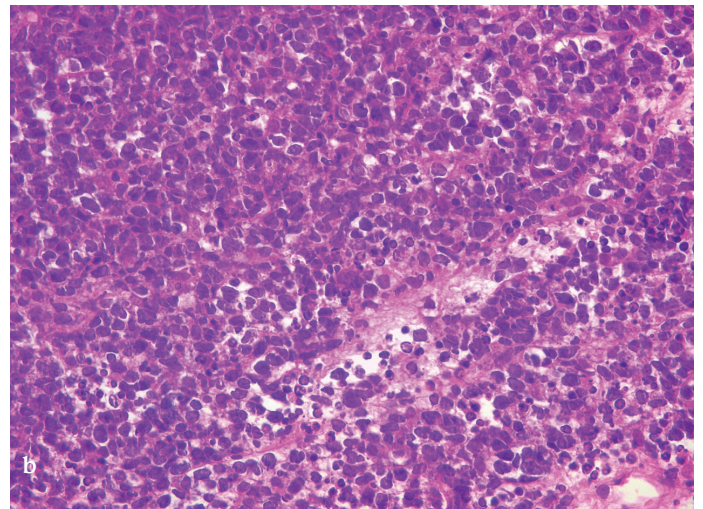
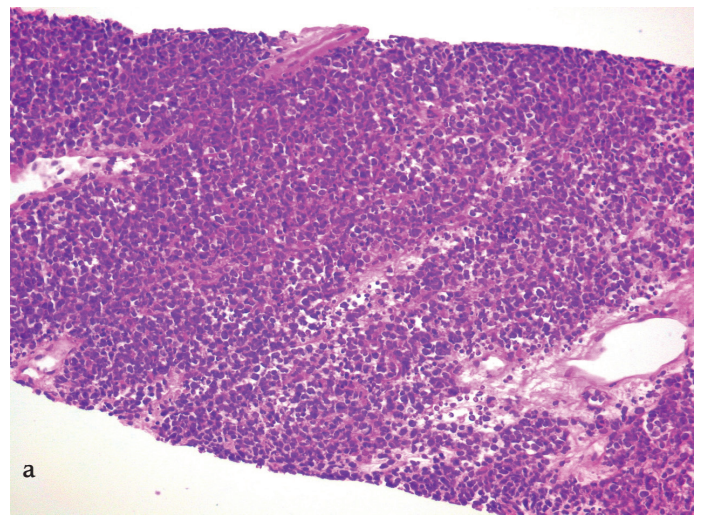


Figure 2. a, b) Histological examination with hematoxylin and eosin staining of thyroid follicles destruction and diffuse growth of lymphocytes

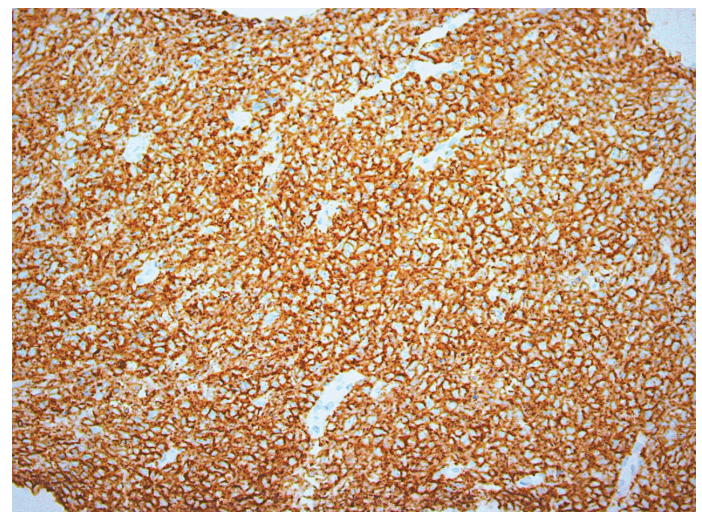


Figure 3. Positive immunohistochemistry stain for CD20

neck revealed a nodular alteration of 2.95 x 3.9 x 5.2 cm in the right thyroid gland and multiple lymph nodes in the neck bilaterally. PET/CT scan confirmed these findings with $SUV_{max} = 16.5$ and 2.5 in the right thyroid gland and lymph nodes, respectively. Chest and abdomen CT scans were normal. Flow cytometry, morphology and cytogenetic analysis did not show any evidence of bone marrow involvement and the CSF was negative for infiltration. The above findings indicated a categorization in the intermediate risk group.

Due to the rarity of the disease in children, the optimal therapy (thyroidectomy or chemotherapy) was debatable. It was finally decided to start chemotherapy only, according to the lymphomes malins B (LMB) 96-group B protocol. This protocol consists of initial induction chemotherapy with intravenous (IV) COP [cyclophosphamide (300 mg/m²), vincristine (1 mg/m²), and prednisolone (60 mg/m²-7 days)] and intrathecal (IT) methotrexate (15 mg) and hydrocortisone (15 mg), followed by two courses of IV COPADM [doxorubicin 60 mg/m², methotrexate 3 g/m², cyclophosphamide 500 mg/m²/day-5 days, vincristine (2 mg/m²), and prednisolone (60 mg/m²-5 days)], IT methotrexate (15 mg) with hydrocortisone (15 mg) and two courses of IV CYM (cytarabine 100 mg/m²/day-5 days and methotrexate 3 g/m²) and IT methotrexate (15 mg), hydrocortisone (15 mg) and cytarabine (30 mg).

The patient responded very well to treatment with a rapid decrease in the size of the thyroid mass after COP. An US of the thyroid gland performed after completion of COP revealed an 80% decrease in the size of the mass. A follow-

up PET/CT scan after the first course of CYM showed that the tumor had totally disappeared. At the time of writing, she was disease-free, 14 months after end of treatment.

Discussion

PTL is an extremely rare malignancy in children (3), and represents only 1-5% of all malignancies of thyroid gland in adults (3). To the best of our knowledge, this is only the second case of a young adolescent with PTL reported in the literature (1).

A comparison of findings between adults and adolescents is depicted in Table 2.

Previous studies have shown that most patients were females aged 50-80 years (4,5,6). PTL presents with progressive swelling of the neck. Compressive symptoms (dyspnea, dysphagia, cough, hoarseness) may develop, as well as general symptoms, such as weight loss, night sweats and fever in 10% (7). The presented patient, however, had no such symptoms (Table 2). HT is a well-known risk factor for PTL with patients having a relative risk of 67-80 times compared to those without thyroiditis (8). The presented patient had a nine-year history of HT before the diagnosis of PTL. Various theories have been proposed to explain the association between HT and PTL. It has been suggested that chronic antigen stimulation of lymphocytes may lead to malignant differentiation (8). In a recent large scale-report of PTL, 154 out of 171 adult patients (90%) had HT diagnosed 1-362 months prior to the diagnosis of lymphoma (9).

Table 2. Comparison between adults and children (two cases reported in literature)

	Adults	Children
Incidence	2/10 ⁶ per year	2 cases
F / M	Five times more common in F	1 F/1 M
Rapid painless enlargement	Yes	Both
Compressive symptoms	Common	None
Cervical lymphadenopathy	Common	None
Hashimoto thyroiditis	Common (67-80-fold risk)	One
Ultrasound findings:		
- Diffuse heterogenous hypoechoic parenchyma	Yes (25%)	Both
- Hypoechoic mass	Yes (67%)	Both
Final diagnosis:		
- FNA	Yes (50-60%)	One
- Core biopsy	In doubtful cases	One
Treatment		
- Chemotherapy and radiotherapy	Yes	Both only chemotherapy
- Surgery	No	None
Prognosis		
- Survival at 5 years	74%	Unknown (both are disease-free 2 years after diagnosis)
- Survival at 10 years	71%	

FNA: fine needle aspiration, M: male, F: female

Many previous studies agree that the most common subtype of PTL is DLBCL followed by MALT lymphoma mixed type. Histopathologically, it is very important to distinguish between the above-mentioned subtypes, as therapeutic management and prognosis are different. On immunohistochemical staining, CD5, CD10 and CD23 are negative in MALT cases and CD19, CD20 and CD45 are usually positive in DLBCL (10). Most DLBCL are Bcl-6 positive and almost half are Bcl-2 positive (11). The presented case was positive for Bc-2 and negative for *MYC*, *DUSP22* and *IRF4* translocations.

US is often the first line investigation in patients with thyroid enlargement and nodules but it is sometimes non diagnostic for PTL. In DLBCL, US usually shows homogenous and hypoechoic internal echoes, with indistinct borders between the lymphomatous and non-lymphomatous tissues. These findings, however, are also typical of severe chronic thyroiditis (12). In a retrospective study of 165 patients with US-suspected malignant thyroid lymphoma based on the US findings, 79 (47.9%) were confirmed as having lymphoma (12). The positive predictive value for diagnosis of diffuse type was reported to be lower, compared to nodular or mixed type (12).

US-guided FNA and CNB are the next steps for the diagnostic strategy. FNA is widely accepted as a diagnostic tool due to its simplicity, safety and its high sensitivity of 83-98% and specificity of 70-92% (13). However, FNA results may be non-diagnostic in 2-24% (14). CNB has been suggested as a complimentary method to FNA. CNB is safe, well-tolerated and reduces the possibility of inconclusive results, as a larger tissue sample is taken when performed by an expert. However, a recent meta-analysis by Li et al. (15) found that FNA and CNB don't differ significantly in sensitivity and specificity for the diagnosis of thyroid malignancy. In the presented case, two FNAs and a CNB were necessary to confirm the diagnosis.

Previously, open surgical biopsy was used to differentiate lymphoma from thyroiditis and carcinoma (16). However, recent advances in immunochemistry have improved the accuracy of FNA. In 119 patients with thyroid lymphoma, Matsuzuka et al. (16) showed that only 78.3% who underwent FNA without immunotyping were diagnosed correctly, while another 12% had borderline cytologic results. In another study, FNA results were highly suggestive of thyroid lymphoma in only five out of 17 (29.4%) (17). Based on such studies, many specialists recommended surgical intervention and open biopsy in all patients due to the perceived limited role of FNA in diagnosing thyroid lymphoma. More recent studies, however, have shown that FNA together with immunophenotyping improves the

accuracy of the results. Therefore, CNB or surgical biopsies are now less often needed (18,19). The expertise of the physician performing the FNA, the amount of tissue taken and the pathologist's experience in interpreting FNA results are important for accurate diagnosis. Therefore, CNB or open biopsies (to obtain enough cells) are the most preferable techniques. CNB and surgical biopsy are comparable regarding the accuracy, but the latter is usually accompanied by trauma and possible complications (18,19).

Regarding the treatment, experience in children and adolescents is limited, since DLBCL is rare in this age group with sparse data on incidence and treatment. Therefore, the optimal approach remains controversial (20). For these reasons the treatment for pediatric/adolescent DLBCL is generally based on established treatment regimen for other extra-nodal NHLs (21). According to histology findings and cancer staging, chemotherapy, loco-regional radiotherapy and surgery may be combined for successful treatment. Surgery seems to play a limited role and is only really necessary in large tumors with compressive symptoms (21). Surgical biopsy and resection have been used for the diagnosis and therapeutic management with significant survival benefit (21). In the presented case, the patient commenced on chemotherapy based on staging.

Our patient responded very well to the chemotherapy protocol with rapid decrease in the thyroid mass. The role of surgical removal of thyroid remains questionable (16). It is not a first line treatment and is limited only either to cases that have failed to respond successfully to chemotherapy or to cases where CNB has failed to establish the precise diagnosis (20).

The intermediate risk disease group, B-cell-NHL (B-NHL), is the largest and most heterogeneous. In FAB/LMB studies 70% of patients can be classified as intermediate risk (group B) and have a 4-year event free survival of 90% (20).

Conclusion

A case of NHL which belonged to the DLBCLs is presented. This was a primary tumor in the thyroid gland, which is extremely rare in children and adolescents. The case responded very well to chemotherapy. NHLs should be considered in the differential diagnosis in children and adolescents presenting with rapidly increasing, hard, and painless mass in the neck, especially on a background of HT.

Ethics

Informed Consent: All authors comply with the guidelines for human studies and also comply with Ethics Guidelines.

The patient and her parents have given their written informed consent to publish this case.

Peer-review: Externally peer-reviewed.

Authorship Contributions

Surgical and Medical Practices: Maria Xatzipsalti, Evangelos Bourousis, Maria Nikita, Dimitra Rontogianni, Myrsini. G. Gkeli, Dionisios Chrysis, Aristeidis Giannakopoulos, Dimitrios Delis, Margarita Baka, Andriani Vazeou, Concept: Maria Xatzipsalti, Evangelos Bourousis, Dionisios Chrysis, Aristeidis Giannakopoulos, Dimitrios Delis, Margarita Baka, Andriani Vazeou, Design: Maria Xatzipsalti, Evangelos Bourousis, Andriani Vazeou, Data Collection or Processing: Maria Xatzipsalti, Evangelos Bourousis, Dionisios Chrysis, Analysis or Interpretation: Maria Xatzipsalti, Evangelos Bourousis, Dimitra Rontogianni, Myrsini. G. Gkeli, Dionisios Chrysis, Aristeidis Giannakopoulos, Dimitrios Delis, Margarita Baka, Andriani Vazeou, Literature Search: Maria Xatzipsalti, Evangelos Bourousis, Maria Nikita, Andriani Vazeou, Writing: Maria Xatzipsalti, Evangelos Bourousis, Maria Nikita, Dimitra Rontogianni, Myrsini. G. Gkeli, Dionisios Chrysis, Aristeidis Giannakopoulos, Andriani Vazeou.

Financial Disclosure: The authors declared that this study received no financial support.

References

1. Marwaha RK, Pritchard J. Primary thyroid lymphoma in childhood: treatment with chemotherapy alone. *Pediatr Hematol Oncol* 1990;7:383-388.
2. Aukema SM, Siebert R, Schuurin E, van Imhoff GW, Kluin-Nelemans HC, Boerma EJ, Kluin PM. Double-hit B-cell lymphomas. *Blood* 2011;117:2319-2331. Epub 2010 Nov 30
3. Graff-Baker A, Roman SA, Thomas DC, Udelsman R, Sosa JA. Prognosis of primary thyroid lymphoma: demographic, clinical, and pathologic predictors of survival in 1,408 cases. *Surgery* 2009;146:1105-1115.
4. Chai YJ, Hong JH, Koo do H, Yu HW, Lee JH, Kwon H, Kim SJ, Choi JY, Lee KE. Clinicopathological characteristics and treatment outcomes of 38 cases of primary thyroid lymphoma: a multicenter study. *Ann Surg Treat Res* 2015;89:295-299. Epub 2015 Nov 27
5. Derringer GA, Thompson LD, Frommelt RA, Bijwaard KE, Heffess CS, Abbondanzo SL. Malignant lymphoma of the thyroid gland: a clinicopathologic study of 108 cases. *Am J Surg Pathol* 2000;24:623-639.
6. Trovato M, Giuffrida G, Seminara A, Fogliani S, Cavallari V, Ruggeri RM, Campenni A. Coexistence of diffuse large B-cell lymphoma and papillary thyroid carcinoma in a patient affected by Hashimoto's thyroiditis. *Arch Endocrinol Metab* 2017;61:643-646.
7. Holm LE, Blomgren H, Löwhagen T. Cancer risks in patients with chronic lymphocytic thyroiditis. *N Engl J Med* 1985;312:601-604.
8. Kossev P, Livolsi V. Lymphoid lesions of the thyroid: review in light of the revised European-American lymphoma classification and upcoming World Health Organization classification. *Thyroid* 1999;9:1273-1280.
9. Watanabe N, Noh JY, Narimatsu H, Takeuchi K, Yamaguchi T, Kameyama K, Kobayashi K, Kami M, Kubo A, Kunii Y, Shimizu T, Mukasa K, Otsuka F, Miyara A, Minagawa A, Ito K, Ito K. Clinicopathological features of 171 cases of primary thyroid lymphoma: a long-term study involving 24553 patients with Hashimoto's disease. *Br J Haematol* 2011;153:236-243. Epub 2011 Mar 4
10. Dralle H, Musholt TJ, Schabram J, Steinmüller T, Frilling A, Simon D, Goretzki PE, Niederle B, Scheuba C, Clerici T, Herrmann M, Kußmann J, Lorenz K, Nies C, Schabram P, Trupka A, Zielke A, Karges W, Luster M, Schmid KW, Vordermark D, Schmoll HJ, Mühlenberg R, Schober O, Rimmele H, Machens A; German Societies of General and Visceral Surgery; Endocrinology; Nuclear Medicine; Pathology; Radiooncology; Oncological Hematology; and the German Thyroid Cancer Patient Support Organization Ohne Schilddrüse leben e.V. German Association of Endocrine Surgeons practice guideline for the surgical management of malignant thyroid tumors. *Langenbecks Arch Surg* 2013;398:347-375. Epub 2013 Mar 3
11. Niitsu N, Okamoto M, Nakamura N, Nakamine H, Bessho M, Hirano M. Clinicopathologic correlations of stage IE/IIIE primary thyroid diffuse large B-cell lymphoma. *Ann Oncol* 2007;18:1203-1208. Epub 2007 Apr 11
12. Ota H, Ito Y, Matsuzuka F, Kuma S, Fukata S, Morita S, Kobayashi K, Nakamura Y, Kakudo K, Amino N, Miyauchi A. Usefulness of ultrasonography for diagnosis of malignant lymphoma of the thyroid. *Thyroid* 2006;16:983-987.
13. American Thyroid Association (ATA) Guidelines Taskforce on Thyroid Nodules and Differentiated Thyroid Cancer; Cooper DS, Doherty GM, Haugen BR, Kloos RT, Lee SL, Mandel SJ, Mazzaferri EL, McIver B, Pacini F, Schlumberger M, Sherman SI, Steward DL, Tuttle RM. Revised American Thyroid Association management guidelines for patients with thyroid nodules and differentiated thyroid cancer. *Thyroid* 2009;19:1167-1214.
14. Yoon JH, Moon HJ, Kim EK, Kwak JY. Inadequate cytology in thyroid nodules: should we repeat aspiration or follow-up? *Ann Surg Oncol* 2011;18:1282-1289. Epub 2011 Feb 19
15. Li L, Chen BD, Zhu HF, Wu S, Wei D, Zhang JQ, Yu L. Comparison of pre-operation diagnosis of thyroid cancer with fine needle aspiration and core-needle biopsy: a meta-analysis. *Asian Pac J Cancer Prev* 2014;15:7187-7193.
16. Matsuzuka F, Miyauchi A, Katayama S, Narabayashi I, Ikeda H, Kuma K, Sugawara M. Clinical aspects of primary thyroid lymphoma: diagnosis and treatment based on our experience of 119 cases. *Thyroid* 1993;3:93-99.
17. Sarinah B, Hisham AN. Primary lymphoma of the thyroid: diagnostic and therapeutic considerations. *Asian J Surg* 2010;33:20-24.
18. Cha C, Chen H, Westra WH, Udelsman R. Primary thyroid lymphoma: can the diagnosis be made solely by fine-needle aspiration? *Ann Surg Oncol* 2002;9:298-302.
19. Sangalli G, Serio G, Zampatti C, Lomuscio G, Colombo L. Fine needle aspiration cytology of primary lymphoma of the thyroid: a report of 17 cases. *Cytopathology* 2001;12:257-263.
20. Egan G, Goldman S, Alexander S. Mature B-NHL in children, adolescents and young adults: current therapeutic approach and emerging treatment strategies. *Br J Haematol* 2019;185:1071-1085.
21. Stein SA, Wartofsky L. Primary thyroid lymphoma: a clinical review. *J Clin Endocrinol Metab* 2013;98:3131-3138. Epub 2013 May 28