



DOI: 10.4274/jcrpe.galenos.2024.2024-10-5

J Clin Res Pediatr Endocrinol 2026;18(Suppl 1):54-58

# A Rare Cause of Neonatal Salt Wasting Syndrome: Clinical Management of a Case Diagnosed with Pseudohypoaldosteronism due to a Novel Homozygous Variant in the *SCNN1B* Gene

✉ Berna Singin<sup>1</sup>, ✉ Zeynep Donbaloğlu<sup>1</sup>, ✉ Ebru Barsal Çetiner<sup>1</sup>, ✉ Kürşat Çetin<sup>1</sup>, ✉ Nurten Özkan Zarif<sup>2</sup>, ✉ Kıymet Çelik<sup>2</sup>, ✉ Ercan Mıhçı<sup>3</sup>, ✉ Özden Altıok Clark<sup>4</sup>, ✉ Hale Tuhani<sup>1</sup>, ✉ Mesut Parlak<sup>1</sup>

<sup>1</sup>Akdeniz University Hospital, Department of Pediatric Endocrinology, Antalya, Türkiye

<sup>2</sup>Akdeniz University Hospital, Department of Neonatology, Antalya, Türkiye

<sup>3</sup>Akdeniz University Hospital, Department of Pediatric Genetics, Antalya, Türkiye

<sup>4</sup>Akdeniz University Hospital, Department of Medical Genetics, Antalya, Türkiye

**Cite this article as:** Singin B, Donbaloğlu Z, Barsal Çetiner E, Çetin K, Özkan Zarif N, Çelik K, Mıhçı E, Altıok Clark Ö, Tuhani H, Parlak M. A rare cause of neonatal salt wasting syndrome: clinical management of a case diagnosed with pseudohypoaldosteronism due to a novel homozygous variant in the *SCNN1B* gene. J Clin Res Pediatr Endocrinol. 2026;18(Suppl 1):54-58

## What is already known on this topic?

Pseudohypoaldosteronism is a rare, salt-wasting syndrome characterized by marked resistance to aldosterone in peripheral target tissues. Differentiating between various adrenal insufficiencies is crucial because the treatment approaches differ. In addition, patient adherence can be challenging due to the necessity of taking large amounts of oral medications.

## What this study adds?

This article outlines our experience treating a patient with pseudohypoaldosteronism caused by an *SCNN1B* variant, emphasizing the difficulties faced in clinical management. In the present case, a homozygous variant c.1234dup (p.Glu412Glyfs\*39) was identified in exon 8 of the *SCNN1B* gene. This variant has not been previously reported.

**Corresponding Author:** Mesut Parlak, MD, Akdeniz University Hospital, Department of Pediatric Endocrinology, Antalya, Türkiye

**E-mail:** mesutparlak@akdeniz.edu.tr **ORCID:** orcid.org/0000-0002-3550-1425

**Conflict of interest:** None declared.

**Received:** 11.10.2024 **Accepted:** 12.12.2024 **Epub:** 26.12.2024 **Publication Date:** 22.05.2026



©Copyright 2026 by Turkish Society for Pediatric Endocrinology and Diabetes / The Journal of Clinical Research in Pediatric Endocrinology published by Galenos Publishing House. Licensed under a Creative Commons Attribution-NonCommercial-NoDerivatives 4.0 (CC BY-NC-ND) International License.

## ABSTRACT

Pseudohypoaldosteronism (PHA) is a rare disorder that, if not promptly recognized and treated, can lead to life-threatening hyperkalemia resulting in cardiac arrest and death. Systemic PHA is caused by variants that deactivate the epithelial sodium channel subunits. Management is challenging due to high-dose oral replacement therapy, and patients with systemic PHA require lifelong treatment. Here, we present the clinical course of a newborn diagnosed with PHA at seven days of age due to severe dehydration, inadequate feeding, vomiting, and lethargy. The infant was found to be homozygous for the variant c.1234dup (p.Glu412Glyfs\*39) in exon 8 of the *SCNN1B* gene. The patient had multiple hospitalizations during follow-up and died at the age of 10 months due to pneumonia. Maintaining a high clinical suspicion for PHA is crucial for initiating treatment and preventing potential cardiac arrest and death in these patients. Further research is needed to determine the significance of such novel mutations in this disease.

**Keywords:** Systemic pseudohypoaldosteronism, hyponatremia, hyperkalemia, salt wasting, sodium polystyrene sulfonate, calcium polystyrene sulfonate

## Introduction

Pseudohypoaldosteronism (PHA) is a rare, salt-wasting syndrome characterized by marked resistance to aldosterone in peripheral target tissues. There are two main types of PHA: type 1 PHA and type 2 PHA. Type 1 PHA may be inherited in an autosomal dominant (AD) or autosomal recessive (AR) manner. The AD form (renal form) is associated with mutations affecting the mineralocorticoid receptor (MR) in principal cells of the kidney, affecting sodium transport. The AR form (systemic form), on the other hand, is linked to mutations in the epithelial sodium channel (ENaC), expressed in various organs including renal tubules, lungs, colon, sweat glands, and salivary glands, which can exacerbate the severity of this form (1). The systemic form, which requires lifelong management, tends to have a more severe course while the renal form often improves within the first two years of life. Type 1 PHA typically presents with symptoms of salt wasting, growth retardation, hyperkalemia, and acidosis, similar to those seen in infants diagnosed with congenital adrenal hyperplasia (CAH) (2). Decreased sodium reabsorption from epithelial cells and the cortical collecting duct leads to volume depletion, thereby reducing the electrochemical gradient that normally supports potassium and hydrogen ion secretion. Besides renal dysfunction, the systemic form of Type 1 PHA is also associated with respiratory tract infections and a positive sweat test (3). Type 2 PHA, known as Gordon syndrome or familial hyperkalemic hypertension, is characterized by hypertension, hyperkalemia, metabolic acidosis, normal kidney function, low-normal plasma renin activity, and aldosterone concentration (4). Type 2 PHA exhibits AD inheritance.

This article discusses our experience in managing a patient with PHA due to an *SCNN1B* variant, highlighting the challenges encountered in clinical management.

## Case Report

A 7-day-old female infant, born via repeat Cesarean section from the second pregnancy of a 23-year-old mother, presented to the hospital with symptoms of vomiting, pallor, lethargy, poor

feeding, and sleepiness. The infant was born at term, weighing 3500 grams (between the 50<sup>th</sup> and 90<sup>th</sup> percentile), with a length of 51 cm (50<sup>th</sup> percentile) and a head circumference of 36 cm (50<sup>th</sup> percentile). Due to the findings of hyponatremia and hyperkalemia upon initial evaluation, a preliminary diagnosis of CAH was considered, prompting referral to our center. There is a history of consanguinity (second-degree cousins) between the mother and father. The infant has a healthy 3.5-year-old male sibling.

On physical examination, her general condition was fair to poor, with altered skin turgor and milia and pustular erythematous rash on her face and neck. There were no ambiguous genitalia or hyperpigmentation noted. Examination of other systems was unremarkable. The patient's laboratory test results are shown in Table 1. Venous blood gas analysis showed a pH of 7.36, bicarbonate (HCO<sub>3</sub>) of 11.5 mmol/L, and base excess (BE) of -11.3 mmol/L. Due to hyperkalemia, the patient was started on appropriate fluid therapy and received treatments including calcium gluconate, glucose-insulin infusion, NaHCO<sub>3</sub> infusion, and inhaled salbutamol. A 25-mg loading dose of IV hydrocortisone was administered, followed by 5 mg of IV stress dosing every 6 hours. In addition, fludrocortisone 0.1 mg twice daily was initiated. However, despite these interventions, the patient's hyperkalemia and hyponatremia remained resistant. Oral calcium polystyrene sulfonate at a dose of 1 g/kg/day and oral salt supplementation (4x1 g/day) were gradually increased. Laboratory findings upon admission to our clinic included spot urine analysis showed sodium levels of 156 mEq/L (normal range: 54-150 mEq/L) and potassium levels of 3.5 mEq/L (normal range: 6.7-21.3 mEq/L) concurrent with serum sodium of 118 mmol/L and potassium of 9.8 mmol/L. The calculated transtubular potassium gradient was low. Based on these laboratory results, hydrocortisone therapy was halted. Fludrocortisone therapy was continued but did not provide benefit. Considering the patient's presentation in the neonatal period, laboratory findings of hyponatremia and hyperkalemia with increased urinary sodium excretion, elevated aldosterone levels, and normal blood pressure, systemic PHA was suspected. Secondary PHA

Table 1. Patient's laboratory results		
	Result	Normal range
Na (mmol/L)	118	136-145
K (mmol/L)	9.8	3.5-5.1
BUN (mg/dL)	25	4-19
Creatinine (mg/dL)	0.52	0.17-0.42
Uric acid (mg/dL)	6.5	2.4-5.7
17-OHP (ng/mL)	9.6	0.051-2.35
ACTH (ng/L)	5.66	7.2-63.3
Serum cortisol (ug/dL)	32.9	4.82-19.5
Renin (ng/mL/hour)	13.1	2.4-37
Aldosterone (ng/dL)	200	3-16

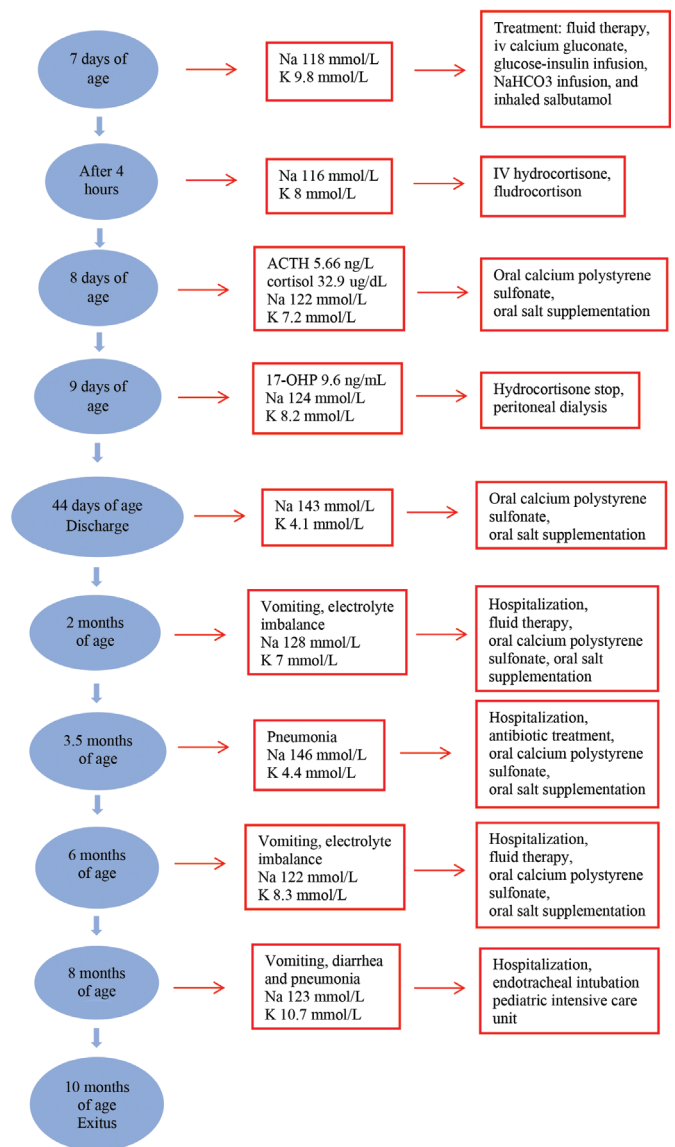
Na: sodium, K: potassium, BUN: blood urea nitrogen, 17-OHP: 17-hydroxyprogesterone, ACTH: adrenocorticotropic hormone

was ruled out based on normal urine analysis, urine culture, and urinary system ultrasonography. Despite increasing the dose of calcium polystyrene sulfonate to 4 g/kg/day and other conventional treatments, the patient's hyperkalemia persisted, necessitating peritoneal dialysis. Potassium levels decreased from 8.2 mmol/L pre-dialysis to 4.3 mmol/L on follow-up. The patient remained stable on treatment with 4x1 g oral salt and 10 g/day of calcium polystyrene sulfonate. She gained 1360 grams during hospitalization, weighing 4620 grams at discharge on the 37<sup>th</sup> day, with treatment being appropriately managed.

This infant was diagnosed with electrolyte imbalance at two months of age, pneumonia at 3.5 months, and again with electrolyte imbalance at six months, requiring hospitalization and treatment each time.

At eight months of age, the patient was brought to the emergency department due to vomiting and diarrhea. Initial tests upon arrival showed sodium at 123 mmol/L and potassium at 10.7 mmol/L. Due to respiratory distress and desaturation, the patient underwent endotracheal intubation and was admitted to the pediatric intensive care unit. Following 55 days of hospitalization for pneumonia, the patient passed away at 10 months of age (Figure 1).

Considering the clinical and laboratory findings suggestive of systemic type 1 PHA, the patient's related genes were examined using next-generation sequencing. Informed consent was obtained from the parents for this study. A homozygous variant c.1234dup (p.Glu412Glyfs\*39) in exon 8 of the *SCNN1B* gene was identified in the infant. This variant, a nucleotide duplication, has not been reported in population genetics studies and is classified as "likely pathogenic" according to ACMG (American College of Medical Genetics) criteria (21). We plan to conduct genetic testing for the patient's family as well, but this remains outstanding at the time of writing.



**Figure 1.** Timeline of case

Na: sodium, K: potassium, 17-OHP: 17-hydroxyprogesterone, ACTH: adrenocorticotropic hormone, HCO<sub>3</sub>: bicarbonate

## Discussion

In this article, we present our observations and the challenges encountered during the treatment process of a newborn with multisystem PHA type 1. Systemic Type 1 PHA is a rare, life-threatening condition. In the neonatal period, salt-wasting syndromes present with various clinical manifestations. Patients may present with nonspecific symptoms such as vomiting, weakness, feeding difficulties, failure to thrive, and increased tendency to sleep, or severe dehydration leading to shock (5). Typically, neonates presenting with these symptoms may initially be misdiagnosed with conditions such as CAH due

to 21-hydroxylase or 3-beta-hydroxysteroid dehydrogenase deficiency, or primary hypoaldosteronism causing salt loss in the neonatal period. The diagnosis of type 1 PHA relies on high plasma aldosterone and renin levels, especially when high-dose mineralocorticoid therapy fails to correct potassium and salt imbalance. Moreover, measurements of 17-hydroxyprogesterone, adrenocorticotropin hormone, cortisol, renin, and aldosterone levels provide clues to distinguish between CAH and type 1 PHA (6). Our patient presented with hyponatremia and hyperkalemia alongside normal genitalia. Hydrocortisone and fludrocortisone were initiated until adrenal androgen results were obtained. The diagnosis of systemic type 1 PHA was confirmed as adrenal hormone levels remained within normal ranges during follow-up. Differential diagnosis in our case included transient aldosterone resistance secondary to urinary tract infection, which was ruled out due to normal urine analysis, urine culture, and urinary system ultrasonography. The co-occurrence of high aldosterone levels with hyponatremia and hyperkalemia supported renal aldosterone resistance guiding our patient's treatment.

Type 1 PHA is classified into renal (OR) and systemic (OD) forms based on mutations in the *NR3C2* gene encoding MR or *SCNN1A*, *SCNN1B*, and *SCNN1G* genes encoding ENaC subunits. The systemic form of type 1 PHA leads to systemic salt loss involving kidneys, colon, sweat, and salivary glands (7). In the presented case, a homozygous variant c.1234dup (p.Glu412Glyfs\*39) was identified in exon 8 of the *SCNN1B* gene. The *SCNN1B* gene, comprising 13 exons and encoding a transmembrane protein with two transmembrane segments totaling 640 amino acids (8), has been associated with pathogenic variants linked to type 1 PHA and Liddle syndrome. It is anticipated that the identified homozygous variant in the *SCNN1B* gene at nucleotide position 1234, a duplication variant, affects protein functions. This variant has not been previously reported in the literature.

A case with a homozygous mutation detected in the promoter region of the ENaC in the *SCNN1B* gene also exhibited recurrent lung infections, similar to our patient. However, in this case, over time, the frequency and severity of these respiratory illnesses showed a tendency to decrease, and the lung condition stabilized after the age of six years (9). In another study reporting a case with a mutation detected in the *SCNN1B* gene, additional clinical features included persistent clear nasal discharge, frequent lower respiratory tract infections associated with wheezing, and developmental delay. This case, which required a gastrostomy at 14 months, showed a significant reduction in hospital admissions (1-2 per year) following the gastrostomy, although recurrent lower respiratory tract infections were still reported despite being four years old when reported (10). Similarly, another case reported recurrent chronic bronchitic attacks during childhood (11).

In another case with a homozygous c.1266-1G > C variant mutation in intron 8 of the *SCNN1B* gene, vomiting and feeding difficulties similar to those observed in our patient were reported (12). The skin findings observed in our patient, which persisted despite treatment, have also been observed in other patients with mutations in the *SCNN1B* gene. Belot et al. (13) observed bullous dermatitis, while Gopal-Kothandapani et al. (8) reported severe eczema. Similarly, another case with a homozygous mutation in the *SCNN1B* gene presented with features mimicking pustular miliaria rubra, crystal deposition on the forehead, Meibomian gland swelling on the eyelids, and dental-like protrusions (11). These skin and ocular findings can aid in distinguishing type 1 PHA from other conditions causing salt loss, like CAH, prompting the evaluation of serum electrolytes through blood tests (14). In the literature, gastrostomy has been required in four cases due to salt loss (10,11,13,15). Although not needed in our patient, during episodes of vomiting, an orogastric tube was used to administer oral therapies. Hyperkalemia can be life-threatening due to the risk of cardiac arrhythmias. Publications have reported peritoneal dialysis being performed to correct hyperkalemia, as required in the present case (6,8,16,17,18,19).

Since systemic Type 1 PHA can be more refractory to treatment, it is essential to learn from less commonly known approaches. Further guidance for sodium polystyrene sulfonate (brand name: Kayexalate, kalexate, and kionex; molecular weight 70,000 atomic mass units; concentration 15 g/60 mL) administration in neonates and infants under the care of endocrinology is necessary (20). There is limited guidance in the literature on specifically how to give sodium polystyrene sulfonate to neonates and infants, specifically the optimally safe method of transitioning from decanting formula to giving it directly. Sodium polystyrene sulfonate dosing in several children between the ages of 1.75 and 3.25 years old ranged from 0.4 to 3.4 g/kg/day; however, the dosing and method of administration varied (2). Initial direct administration is not always feasible in neonates, to minimize risks such as gastrointestinal bleeding (2). Sodium polystyrene sulfonate can effectively treat hyperkalemia in type 1 PHA, but it is not routinely available in our country. Therefore, we used calcium polystyrene sulfonate in the treatment of our patient.

## Conclusion

Clinical suspicion of PHA, aggressive treatment with IV hydration, sodium and bicarbonate supplementation, and correction of hyperkalemia are crucial. Publishing patients' clinical symptoms and genetic changes, and establishing clearer links between reported mutations and clinical outcomes, will lead to earlier clinical diagnosis and effective genetic counseling for families affected by PHA.

### Ethics

**Informed Consent:** Written informed consent of the parents was obtained for this case report.

### Footnotes

#### Authorship Contributions

Surgical and Medical Practices: Berna Singin, Zeynep Donbaloğlu, Ebru Barsal Çetiner, Kürşat Çetin, Nurten Özkan Zarif, Kıymet Çelik, Hale Tuhan, Mesut Parlak, Concept: Berna Singin, Zeynep Donbaloğlu, Ebru Barsal Çetiner, Kürşat Çetin, Hale Tuhan, Mesut Parlak, Design: Berna Singin, Zeynep Donbaloğlu, Ercan Mıhçı, Mesut Parlak, Data Collection and Processing: Berna Singin, Zeynep Donbaloğlu, Ebru Barsal Çetiner, Kürşat Çetin, Nurten Özkan Zarif, Kıymet Çelik, Ercan Mıhçı, Özden Altıok Clark, Hale Tuhan, Mesut Parlak, Analysis or Interpretation: Berna Singin, Zeynep Donbaloğlu, Ercan Mıhçı, Özden Altıok Clark, Literature Search: Berna Singin, Mesut Parlak, Writing: Berna Singin, Mesut Parlak.

**Financial Disclosure:** The authors declared that this study received no financial support.

## References

1. Pujo L, Fagart J, Gary F, Papadimitriou DT, Claës A, Jeunemaître X, Zennaro MC. Mineralocorticoid receptor mutations are the principal cause of renal type 1 pseudohypoaldosteronism. *Hum Mutat.* 2007;28:33-40.
2. Nur N, Lang C, Hodax JK, Quintos JB. Systemic pseudohypoaldosteronism type I: a case report and review of the literature. *Case Rep Pediatr.* 2017;2017:7939854. Epub 2017 Apr 18
3. Amin N, Alvi NS, Barth JH, Field HP, Finlay E, Tyerman K, Frazer S, Savill G, Wright NP, Makaya T, Mushtaq T. Pseudohypoaldosteronism type 1: clinical features and management in infancy. *Endocrinol Diabetes Metab Case Rep.* 2013;2013:130010. Epub 2013 Aug 30
4. Bonny O, Rossier BC. Disturbances of Na/K balance: pseudohypoaldosteronism revisited. *J Am Soc Nephrol.* 2002;13:2399-2414.
5. Akın MA, Çoban D, Kurtoğlu S, Akın L, Akçaş M. Yenidoğanda iki tuz kaybı olgusu: primer ve sekonder psödohipoaldosteronizm. *Erciyes Tıp Dergisi.* 2010;32:207-212. [Turkish]
6. Gao Z, Sun J, Cai C, Gong X, Ma L. Pseudohypoaldosteronism type 1b in fraternal twins of a Chinese family: report of two cases and literature review. *Arch Endocrinol Metab.* 2023;67:e000620.
7. Riepe FG. Clinical and molecular features of type 1 pseudohypoaldosteronism. *Horm Res.* 2009;72:1-9. Epub 2009 Jun 30
8. Gopal-Kothandapani JS, Doshi AB, Smith K, Christian M, Mushtaq T, Banerjee I, Padidela R, Ramakrishnan R, Owen C, Cheetham T, Dimitri P. Phenotypic diversity and correlation with the genotypes of pseudohypoaldosteronism type 1. *J Pediatr Endocrinol Metab.* 2019;32:959-967.
9. Thomas CP, Zhou J, Liu KZ, Mick VE, MacLaughlin E, Knowles M. Systemic pseudohypoaldosteronism from deletion of the promoter region of the human Beta epithelial na(+) channel subunit. *Am J Respir Cell Mol Biol.* 2002;27:314-319.
10. Edelheit O, Hanukoglu I, Gizewska M, Kandemir N, Tenenbaum-Rakover Y, Yurdakök M, Zajaczek S, Hanukoglu A. Novel mutations in epithelial sodium channel (ENaC) subunit genes and phenotypic expression of multisystem pseudohypoaldosteronism. *Clin Endocrinol (Oxf).* 2005;62:547-553.
11. Nobel YR, Lodish MB, Raygada M, Rivero JD, Faucz FR, Abraham SB, Lyssikatos C, Belyavskaya E, Stratakis CA, Zilbermint M. Pseudohypoaldosteronism type 1 due to novel variants of *SCNN1B* gene. *Endocrinol Diabetes Metab Case Rep.* 2016;2016:150104. Epub 2016 Jan 7
12. Dogan CS, Erdem D, Mesut P, Merve A, Sema A, Iffet B, Afig B. A novel splice site mutation of the beta subunit gene of epithelial sodium channel (ENaC) in one Turkish patient with a systemic form of pseudohypoaldosteronism Type 1. *J Pediatr Endocrinol Metab.* 2012;25:1035-1039.
13. Belot A, Ranchin B, Fichtner C, Pujo L, Rossier BC, Liutkus A, Morlat C, Nicolino M, Zennaro MC, Cochat P. Pseudohypoaldosteronisms, report on a 10-patient series. *Nephrol Dial Transplant.* 2008;23:1636-1641.
14. Reddy G, Panigrahy N. Unusual skin and eyelid changes in a neonate with pseudohypoaldosteronism. *Archives of Disease in Childhood-Fetal and Neonatal Edition.* 2023;108:285-.
15. Saxena A, Hanukoglu I, Saxena D, Thompson RJ, Gardiner RM, Hanukoglu A. Novel mutations responsible for autosomal recessive multisystem pseudohypoaldosteronism and sequence variants in epithelial sodium channel alpha-, beta-, and gamma-subunit genes. *J Clin Endocrinol Metab.* 2002;87:3344-3350.
16. Güran T, Değirmenci S, Bulut İK, Say A, Riepe FG, Güran Ö. Critical points in the management of pseudohypoaldosteronism type 1. *J Clin Res Pediatr Endocrinol.* 2011;3:98-100. Epub 2011 Jun 8
17. Saravanapandian N, Paul S, Matthai J. Pseudohypoaldosteronism type 1: a rare cause of severe dyselectrolytemia and cardiovascular collapse in neonates. *J Clin Neonatol.* 2012;1:224-226.
18. Sharma R, Pandey M, Kanwal SK, Zennaro MC. Pseudohypoaldosteronism type 1: management issues. *Indian Pediatr.* 2013;50:331-333.
19. Karacan Küçükali G, Çetinkaya S, Tunç G, Oğuz MM, Çelik N, Akkaş KY, Şenel S, Güleray Lafcı N, Savaş Erdeve Ş. Clinical management in systemic type pseudohypoaldosteronism due to *SCNN1B* variant and literature review. *J Clin Res Pediatr Endocrinol.* 2021;13:446-451. Epub 2020 Aug 25
20. Alkhatib EH, Bartlett D, Kanakatti Shankar R, Regier D, Merchant N. Case report: Early molecular confirmation and sodium polystyrene sulfonate management of systemic pseudohypoaldosteronism type I. *Front Endocrinol (Lausanne).* 2024;14:1297335.
21. Richards S, Aziz N, Bale S, Bick D, Das S, Gastier-Foster J, Grody WW, Hegde M, Lyon E, Spector E, Voelkerding K, Rehml HL; ACMG Laboratory Quality Assurance Committee. Standards and guidelines for the interpretation of sequence variants: a joint consensus recommendation of the American College of Medical Genetics and Genomics and the Association for Molecular Pathology. *Genet Med.* 2015;17:405-424. Epub 2015 Mar 5