



DOI: 10.4274/jcrpe.galenos.2024.2024-3-8

J Clin Res Pediatr Endocrinol 2026;18(Suppl 1):6-11

Autosomal Recessive Hypophosphatemic Rickets Type 2 Associated with a Novel *ENPP1* Variant in a Taiwanese Girl

Han-Yi Lin¹, Ni-Chung Lee², Meng-Ju Melody Tsai³, Ting-Ming Wang⁴, Yi-Ching Tung⁵

¹National Taiwan University Hospital Hsinchu Branch, Department of Pediatrics, Hsinchu, Taiwan

²National Taiwan University Hospital, Department of Medical Genetics, Taipei, Taiwan

³National Taiwan University Hospital Yunlin Branch, Department of Pediatrics, Douliu, Yunlin, Taiwan

⁴National Taiwan University Hospital, Department of Orthopedic Surgery, Taipei, Taiwan

⁵National Taiwan University Hospital, Department of Pediatrics, Taipei, Taiwan

Cite this article as: Lin H-Y, Lee N-C, Tsai M-J M, Wang T-M, Tung Y-C. Autosomal recessive hypophosphatemic rickets type 2 associated with a novel *ENPP1* variant in a Taiwanese girl. J Clin Res Pediatr Endocrinol. 2026;18(Suppl 1):6-11

What is already known on this topic?

Autosomal recessive hypophosphatemic rickets type 2 (ARHR2) is a rare genetic disorder caused by a variant of the gene encoding ectonucleotide pyrophosphatase/phosphodiesterase 1 (*ENPP1*). Use of oral phosphates and active vitamin D can improve bowing of the legs and growth although generalized arterial calcification may occur and should be monitored.

What this study adds?

The present case describes a patient with a novel *ENPP1* variant, c.1092-42A>G. ARHR2 should be considered if hypophosphatemic rickets with elevated FGF23 level without dominant inheriting family history, even in patients of normal stature.

ABSTRACT

Autosomal recessive hypophosphatemic rickets (ARHR) type 2 (ARHR2) is a rare form of hypophosphatemic rickets (HR) caused by a variant of the gene encoding ectonucleotide pyrophosphatase/phosphodiesterase 1 (*ENPP1*). Our patient presented with a history of unsteady gait and progressively bowing legs that had commenced at the age of one year. Laboratory tests revealed elevated fibroblast growth factor 23 level, hypophosphatemia, and high urine phosphate level. Radiography revealed the typical features of rickets. Next-generation sequencing identified a previously reported c.783C>G (p.Tyr261Ter) and a novel c.1092-42A>G variant in *ENPP1*. The patient was prescribed oral phosphates and active vitamin D and underwent guided growth of both distal femora and proximal tibiae commencing at the age of three years. No evidence of generalized arterial calcification was apparent during follow-up, and growth rate was satisfactory.

Corresponding Author: Yi-Ching Tung, MD, National Taiwan University Hospital, Department of Pediatrics, Taipei, Taiwan

E-mail: dtped004@gmail.com **ORCID:** orcid.org/0000-0003-0466-3891

Conflict of interest: None declared

Received: 30.04.2024 **Accepted:** 08.06.2024 **Epub:** 16.07.2024 **Publication Date:** 22.05.2026



©Copyright 2026 by Turkish Society for Pediatric Endocrinology and Diabetes / The Journal of Clinical Research in Pediatric Endocrinology published by Galenos Publishing House. Licensed under a Creative Commons Attribution-NonCommercial-NoDerivatives 4.0 (CC BY-NC-ND) International License.

Keywords: Encoding ectonucleotide pyrophosphatase/phosphodiesterase 1 (ENPP1), fibroblast growth factor 23 (FGF23), hypophosphatemic rickets

Introduction

Hereditary hypophosphatemic rickets (HR) is a rare disorder characterized by renal phosphate wasting, which in turn impairs bone matrix mineralization. In recent decades, the role played by a major phosphatonin, fibroblast growth factor 23 (FGF23), has been clarified. FGF23 is secreted by osteocytes to regulate phosphate metabolism by reducing renal phosphate reabsorption (1). FGF23 also impairs 1,25 dihydroxyvitamin D activation. The most common form of FGF23-related HR is X-linked HR caused by mutational inactivation of the gene encoding the phosphate-regulating endopeptidase (2). However, several other types of FGF23-related HR are inherited in both autosomal-dominant and -recessive manners. Of these, autosomal-recessive HR type 2 (ARHR2), caused by bi-allelic pathogenic variants of the gene encoding ectonucleotide pyrophosphatase/phosphodiesterase 1 (*ENPP1*), is rare. Variants in *ENPP1* were first associated with generalized arterial calcification of infancy (GACI) (3). GACI may trigger sudden death before six months of age. Variants in *ENPP1* also increase serum FGF23 levels (4,5), in turn causing autosomal-recessive HR. Here, we report a girl with bowed legs and hypophosphatemia who was finally diagnosed as a rare case of ARHR2.

Case Report

A 26-month-old girl visited our pediatric endocrine clinic. Her parents reported frequent falls, an unsteady gait, and progressive leg bowing that had commenced more than one year earlier. She had been born prematurely, at 35 weeks gestation, and weighed 2,480 g at birth. Her developmental milestones were within the normal ranges. There was no family history of sudden infant death or genu varum. At the first visit, her height was 88.4 cm (50-75th percentile) and her weight 14.8 kg (90-97th percentile). Physical examination revealed bilateral genu varum and widening of the wrists and especially the ankles (Figure 1A). Neither rachitic rosary nor frontal bossing was observed. Radiography revealed fraying, splaying, and cupping of the metaphyses of both knees, as well as bowed legs with severe deviations in the mechanical axes (Figure 1B). Laboratory tests revealed an elevated alkaline phosphatase (ALP) level (674 U/L; normal range, 69-325 U/L), normocalcemia, hypophosphatemia (phosphate level, 0.97 mmol/L; normal range, 1.2-2.2 mmol/L), and a normal serum intact parathyroid hormone (iPTH) level. The ratio of the tubular maximum reabsorption of phosphate to the glomerular filtration rate was 2.8 mg/dL (normal range, 2.9-6.5 mg/dL), indicating insufficient renal tubular phosphate reabsorption despite the hypophosphatemia. The serum FGF23

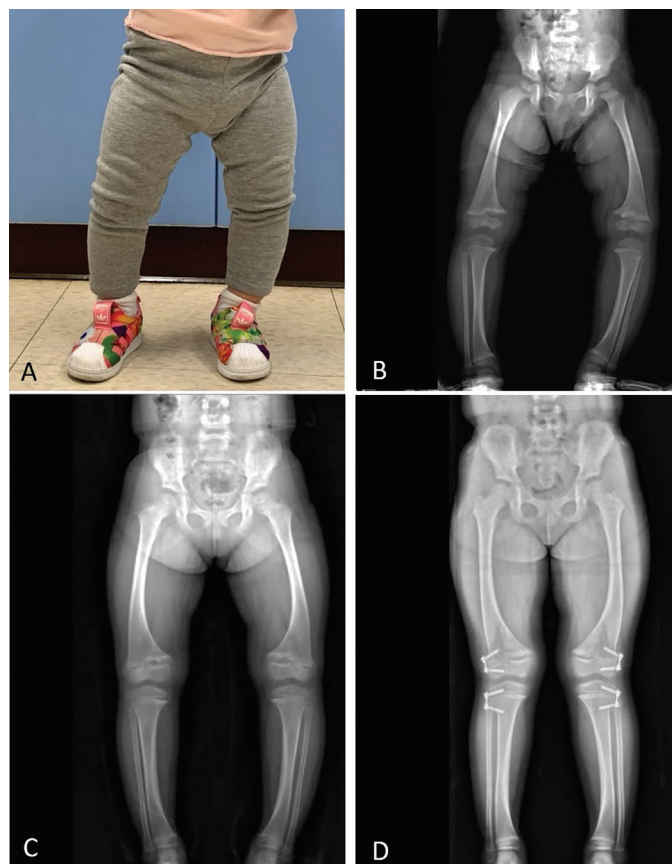

Figure 1. A) Bowlegs at diagnosis, B) X-ray of lower extremities at diagnosis, C) X-ray of lower extremities before guided growth, D) X-ray of lower extremities after guided growth and treatment of phosphate and calcitriol

level was elevated at 84.98 pg/mL (normal range, 8-54.3 pg/mL), leading to a diagnosis of FGF23-related HR. The biochemical data for the patient and her parents are listed in Table 1.

Whole-exome sequencing (WES) revealed the presence of the *ENPP1* compound heterozygous variant c.783C>G (p.Tyr261Ter; regarded as “pathogenic” by the American College of Medical Genetics) in the mother and c.1092-42A>G in the father (“likely pathogenic”). SpliceAI software predicted that c.1092-42A>G is a “gain of acceptor” variant (delta score 0.79) (Figure 2). No vessel calcification was apparent on cardiac sonography. There were no symptoms and signs of hypertension, renal failure or heart failure during follow-up.

We commenced conventional therapy (40 mg/kg/day) phosphate salts. This dose was then titrated up to 50 mg/kg/day and combined with active vitamin D at 15-25 ng/kg/day.

Table 1. The auxological and biochemical data of patient and her parents

	Patient	Father	Mother
Height, cm	88.4	179	158
Height, SDS	0.61	1.32	-0.29
Serum			
Ca, mmol/L	2.68 (2.2-2.7)	2.49 (2.2-2.7)	2.31 (2.2-2.7)
P, mmol/L	0.97 (1.2-2.2)	1.0 (0.8-1.4)	0.97 (0.8-1.4)
Mg, mmol/L	0.81 (0.7-1.2)	0.90 (0.7-1.2)	0.84 (0.7-1.2)
ALP, U/L	674 (69-325)	67 (28-95)	37 (28-95)
Cre, umol/L	26.53 (25-60)	61.89 (50-110)	44.21 (65-120)
iPTH, pg/mL	37.5 (15-70)	110.4 (15-70)	80.9 (15-70)
25(OH)D, ng/mL	28.5 (20-50)	29.0 (20-50)	22.4 (20-50)
FGF23, pg/mL	84.98 (8-54.3)		
Urine			
TRP, %	92.7 (85-95)	86.7 (88-90)	92.95 (88-90)
Tmp/GFR, mg/dL	2.8 (2.9-6.5)	2.7 (2.5-4.5)	2.8 (2.5-4.5)

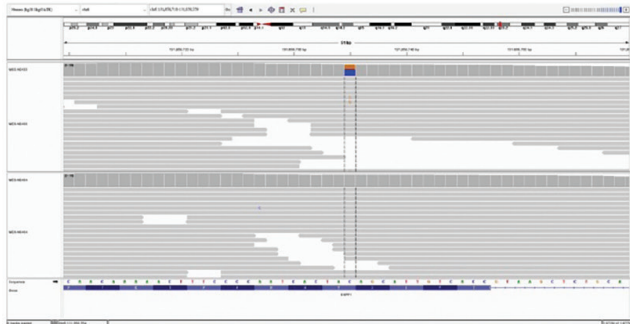
Reference values are presented in parenthesis for age-specific criteria.
 SDS: standard deviation score, Ca: calcium, P: phosphate, Mg: magnesium, ALP: alkaline phosphatase, Cre: creatinine, iPTH: intact parathyroid hormone, 25(OH)D: 25-hydroxyvitamin D, FGF23: fibroblast growth factor 23, TRP: tubular reabsorption of phosphate, Tmp/GFR: ratio of the maximum rate of tubular phosphate reabsorption to the glomerular filtration rate

After one year of this therapy, guided growth of both distal femora and proximal tibiae commenced when she was 3 years and 4 months old because of progressive genu varum (Figure 1C). The biochemical data gradually improved, with the ALP level decreasing to 460 U/L. Follow-up radiography revealed that both femoral metaphyses had healed, and that the mechanical axis deviations of the lower extremities had been corrected (Figure 1D). Her growth curve remained within the normal range, and neither bony nor gastrointestinal discomfort was reported.

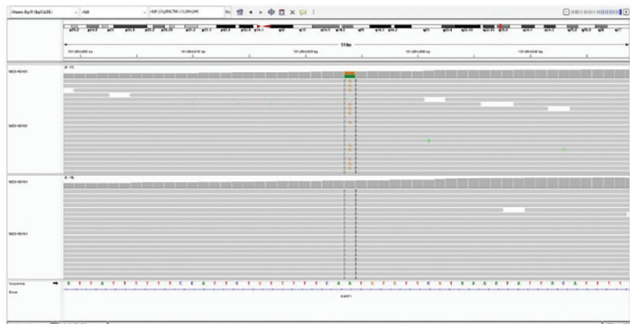
Methods

Serum total calcium, phosphorus, magnesium, creatinine and ALP and urine phosphorus and creatinine were assayed using an automatic biochemical analyzer (Beckman Coulter, AU analysers, Brea, California, USA). Serum iPTH and 25-hydroxy vitamin D (25-OHD) levels were measured by chemiluminescence assay (ARCHITECT system, Abbott, North Chicago, IL, USA). FGF23 was measured by two-site enzyme-linked immunosorbent assay (FGF23 ELISA kit, KAINOS), Laboratories Inc, Bunkyo-ku, Tokyo, Japan. The WES data were generated using Nova Seq platforms (Illumina Inc., San Diego, CA, USA) DNA was extracted from blood samples. Sequenced was done by the captured-based method (Roche KAPA HyperExome, Wilmington, MA, USA). Raw reads

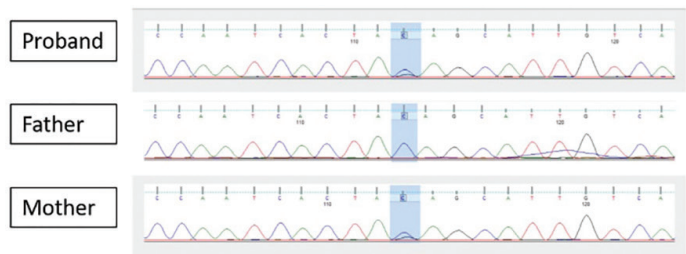
ENPP1 c.783C>G (p.Tyr261Ter)



ENPP1 c.1092-42A>G



ENPP1 c.783C>G (p.Tyr261Ter)



ENPP1 c.1092-42A>G

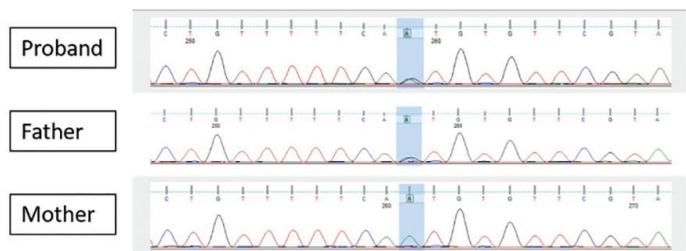


Figure 2. Integrative Genomics Viewer image and Sanger sequencing electropherograms of the variants identified in this patient and her parents
 ENPP1: ectonucleotide pyrophosphatase/phosphodiesterase 1

were mapped to GRhg38 genome and variants were called by the BWA (Burrows-Wheeler Aligner. <http://bio-bwa.sourceforge.net>), GATK (Genome Analysis Toolkit, Broad Institute: <https://gatk.broadinstitute.org>) and ANNOVAR, (Wang Genomics Lab: <http://annovar.openbioinformatics.org>).

Discussion

ENPP1 is an enzyme of the cell membrane that degrades adenosine triphosphate into adenosine monophosphate and pyrophosphate (PPi). PPi inhibits hydroxyapatite crystal deposition and thus plays an essential role in reducing calcification. A PPi deficiency triggers pathological vascular calcification (6). Inactivating *ENPP1* variants were first reported in eight unrelated children with GACI, formerly termed idiopathic infantile arterial calcification. The clinical manifestations include calcification of the elastic internal laminae of muscle arteries and stenosis attributable to myointimal proliferation (3). GACI is associated with a mortality rate of 55% within the first six months of life, caused by heart failure, arterial hypertension, multiorgan failure, and/or myocardial infarction. GACI is sometimes characterized by intimal proliferation without calcification with clinical findings of hypertension, pulmonary hypertension, and ischemic changes due to arterial stenosis (7). Survivors exhibit ectopic calcification and an elevated serum FGF23 level (8). Kaplan-Meier analysis predicted that survivors would develop HR before the age of 14 years (8). During follow-up, 5 of 19 (26.3%) survivors exhibited HR with renal phosphate loss (9), which was assumed to reflect an attempt to protect against arterial calcification (3). One of five HR patients treated with phosphates and calcitriol presented with worsening arterial stenoses (9). However, several later reports claimed that long-term treatment of HR alleviated bone pain and improved growth without increasing vascular calcification (8,10).

ARHR2 was first reported in a family of Bedouin origin (5). The earlier suggestion that hypophosphatemia protects arteries was replaced by the realization that excess FGF23 is the major pathogenetic feature in patients with *ENPP1* variants. However, the mechanism by which such variants increase the FGF23 level remains unknown (4,5). It was observed that *ENPP1*-deficient mice exhibit increased *FGF23* expression (11). The inactivation of *ENPP1* reduces PPi levels in soft tissues and results in local phosphate depletion in bone. The defect in bone mineralization causes increased FGF23 expression (12). In addition, it has been suggested that an increased level of FGF23 is an adaptive physiological response (13). ARHR2 patients exhibit short stature, early fusion of cranial sutures, rachitic skeletal deformities, lower limb deformities, progressive varus deformities, and bone pain (13). Some reported cases presented with progressive conductive hearing loss (14), pseudoxanthoma (15) and ossification of the posterior longitudinal ligament (16), all of which reflect ectopic calcification. Any family history of

GACI, HR, and/or consanguinity should be carefully noted. In our patient, radiography identified typical rachitic traits, especially in the lower extremities. Laboratory tests revealed elevated FGF23-induced hypophosphatemia and increased urine phosphate excretion. A definitive diagnosis was made possible by *ENPP1* sequencing. Our patient presented with lower limb varus deformities at the time that she began to walk, and the deformities gradually worsened. The clinical presentation, laboratory data, and radiological findings were typical of HR, but her height was not short, perhaps attributable to high mid-parental height. ARHR2 should be considered if HR is accompanied by an elevated FGF23 level, even in patients of normal stature.

A total of 140 *ENPP1* variants have been identified to date, of which missense variants are the most common (70%) (17). In our patient, the variant in exon 7 (c.783C>G) has been reported to be associated with both GACI (18) and ARHR2 (19). In Chinese patients, c.783C>G is the most common ARHR2 variant (19). However, the c.1092-42A>G variant in intron 10 is a novel ARHR2 variant. No obvious correlations between *ENPP1* variants and phenotypes have yet been reported (Figure 3) and even siblings with the same variants differ markedly in phenotype (4,8,20).

ARHR2 treatment is generally the same as that for HR, which comprises phosphate and calcitriol supplementation to increase the serum phosphate level and normalize the ALP level. The aims are to eliminate limb deformities and bone pain and to promote growth. Gastrointestinal symptoms, such as abdominal pain and diarrhea, are acute side effects of phosphate supplementation, reducing adherence (13,21). Boyce et al. (22) recommended the initial doses of phosphate to be 25-30 mg/kg/day and calcitriol at 15 ng/kg/day. Previous reports have described the dosage of phosphate to range from 18 to 62.5 mg/kg/day and calcitriol from 10.2 to 37.5 ng/kg/day (4,10,14,16). In patients with a history of GACI, the maximum dosage was 18 mg/kg/day of phosphate and 18 ng/kg/day of calcitriol (10). Although there is no clear opinion, lower doses than in other HR types are recommended. No obvious association was apparent between worsening vascular calcification and treatment with phosphate and calcitriol after long-term follow-up (4,10). However, close monitoring of biochemical parameters and vascular calcification status is essential before and during treatment.

Surgical intervention may be necessary if a bone deformity progresses (23), and regular orthopedic follow-up must be scheduled (10,21). In our case, after phosphate and active vitamin D supplementation, guided growth of both distal femora and proximal tibiae was required because of progressive mechanical axial deviations. Both femoral metaphyses healed, the bowing of the legs improved, and the growth curve remained within the normal range. Since 2018, burosumab, a monoclonal antibody targeting FGF-23, has afforded good results in patients

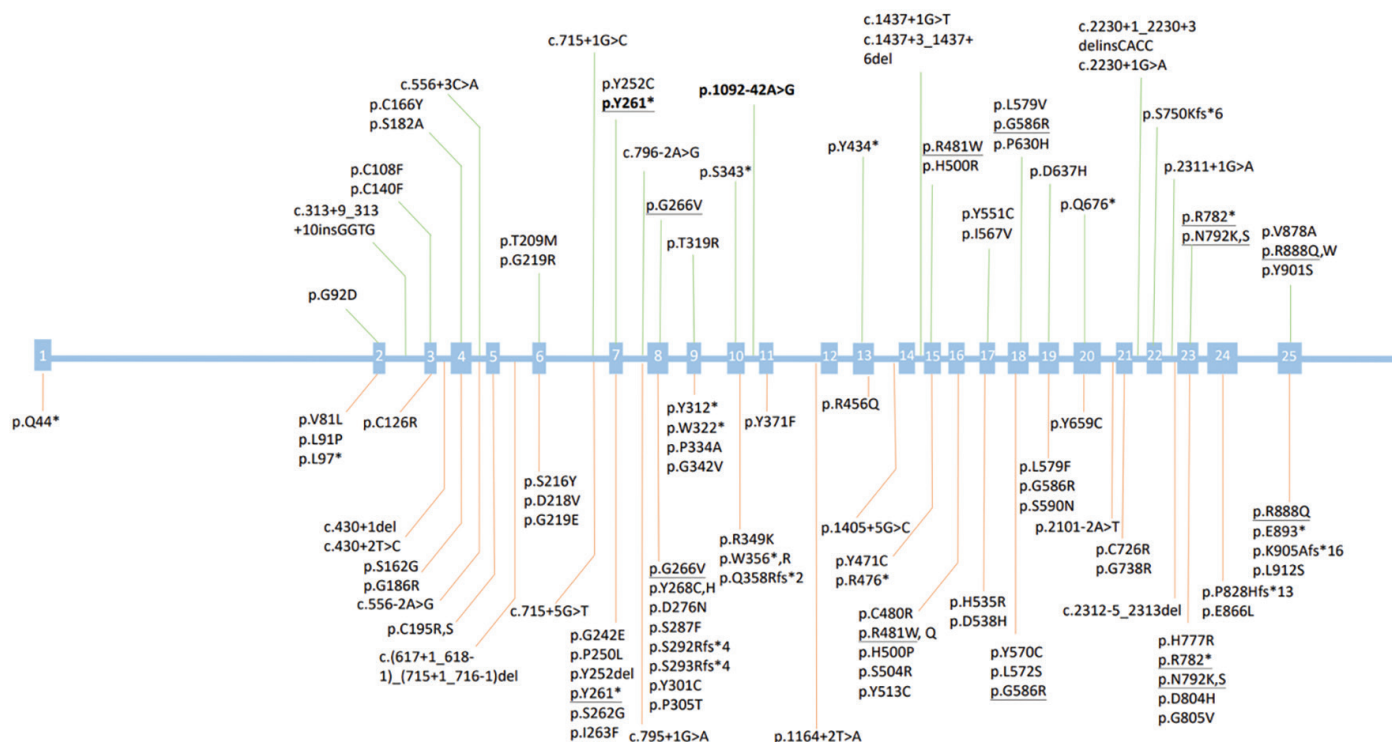


Figure 3. ENPP1 variants identified in patients with ARHR2 and GACI. The upper part shows variants associated with ARHR2, highlighted with a green line. In the lower part, other variants associated with GACI are indicated by an orange line. Variants associated with both GACI and ARHR2 are shown underlined. The variants of our patient are highlighted in bold

ENPP1: ectonucleotide pyrophosphatase/phosphodiesterase 1, ARHR2: autosomal recessive hypophosphatemic rickets type 2, GACI: generalized arterial calcification of infancy

with X-linked HR (24). Renal tubular phosphate reabsorption and linear growth improved, and the severity of the bone pain and rickets lessened. However, it has been suggested that burosumab may worsen ectopic calcification by upregulating ALP and downregulating Ppi. Stern et al. (25) reported a patient with GACI and HR with ENPP1 variants, in whom cardiac calcification worsened after treatment with burosumab for 20 months. Thus, the utility of burosumab in patients with ARHR2 remains controversial. This highlights the need to identify relevant variants before prescribing burosumab for HR patients. In ENPP1-deficient mice, ENPP1 replacement therapies reduced pathological calcification and enhanced growth (26), thus showing considerable promise.

Study Limitations

There are two limitations in our case report. GACI is one of the presentations of ENPP1 deficiency. We had followed up cardiac sonography without evidence of GACI till now. A computed tomography scan would be arranged either when symptoms develop or years later. The second one is that the novel intronic variant is pathogenic on *in silico* analyses, yet the functional analyses of this variant have not been conducted.

Conclusion

We report a novel ENPP1 variant in a Taiwanese patient with compound heterozygous ARHR2. The skeletal varus deformity was similar to those of previous cases with ENPP1 variants, but the stature of the index case was normal. Conventional treatment with phosphates and activated vitamin D promoted radiological bone healing and sustained growth without any evidence of vascular or ectopic calcification. However, long-term meticulous monitoring is essential for such patients.

Ethics

Informed Consent: Written informed guardian consent was obtained from the patient for publication of this case report and any accompanying images.

Footnotes

Authorship Contributions

Surgical and Medical Practices: Han-Yi Lin, Meng-Ju Melody Tsai, Ting-Ming Wang, Yi-Ching Tung, Concept: Han-Yi Lin, Ni-Chung Lee, Meng-Ju Melody Tsai, Ting-Ming Wang, Yi-Ching Tung, Design: Han-Yi Lin, Ni-Chung Lee, Ting-Ming Wang, Yi-Ching Tung, Data Collection or Processing: Han-Yi Lin, Ni-Chung Lee, Meng-Ju Melody

Tsai, Yi-Ching Tung, Analysis or Interpretation: Han-Yi Lin, Ni-Chung Lee, Yi-Ching Tung, Literature Search: Han-Yi Lin, Meng-Ju Melody Tsai, Yi-Ching Tung, Writing: Han-Yi Lin, Ting-Ming Wang, Yi-Ching Tung.

Financial Disclosure: The authors declared that this study received no financial support.

References

1. Fukumoto S. FGF23-related hypophosphatemic rickets/osteomalacia: diagnosis and new treatment. *J Mol Endocrinol*. 2021;66:R57-R65.
2. Francis F, Hennig S, Korn B, Reinhardt R, de Jong P, Poustka A, Lehrach H, Rowe PSN, Goulding JN, Summerfield T, Mountford R, Read AP, Popowska E, Pronicka E, Davies KE, O'Riordan JLH, Econs MJ, Nesbitt T, Drezner MK, Oudet C, Pannetier S, Hanauer A, Strom TM, Meindl A, Lorenz B, Cagnoli B, Mohnike KL, Murken J, Meitinger T. A gene (PEX) with homologies to endopeptidases is mutated in patients with X-linked hypophosphatemic rickets. The HYP consortium. *Nat Genet*. 1995;11:130-136.
3. Rutsch F, Ruf N, Vaingankar S, Toliat MR, Suk A, Höhne W, Schauer G, Lehmann M, Roscioli T, Schnabel D, Epplen JT, Knisely A, Superti-Furga A, McGill J, Filippone M, Sinaiko AR, Vallance H, Hinrichs B, Smith W, Ferre M, Terkeltaub R, Nürnberg P. Mutations in ENPP1 are associated with 'idiopathic' infantile arterial calcification. *Nat Genet*. 2003;34:379-81.
4. Lorenz-Depiereux B, Schnabel D, Tiosano D, Häusler G, Strom TM. Loss-of-function ENPP1 mutations cause both generalized arterial calcification of infancy and autosomal-recessive hypophosphatemic rickets. *Am J Hum Genet*. 2010;86:267-272. Epub 2010 Feb 4
5. Levy-Litan V, Hershkovitz E, Avizov L, Leventhal N, Bercovich D, Chalifa-Caspi V, Manor E, Buriakovsky S, Hadad Y, Goding J, Parvari R. Autosomal-recessive hypophosphatemic rickets is associated with an inactivation mutation in the ENPP1 gene. *Am J Hum Genet* 2010;86:273-278. Epub 2010 Feb 4
6. Goding JW, Grobden B, Slegers H. Physiological and pathophysiological functions of the ecto-nucleotide pyrophosphatase/phosphodiesterase family. *Biochim Biophys Acta*. 2003;1638:1-19.
7. Dursun F, Turan İ, Bitkin EÇ, Bayramoğlu E, Çayır A, Erdeve ŞS, Çakır EDP, Çamtosun E, Dilek SO, Kırmızıbekmez H, Eser M, Türkyılmaz A, Karagüzel G. Natural history of ENPP1 deficiency: Nationwide Turkish Cohort Study of autosomal-recessive hypophosphatemic rickets type 2. *Clin Endocrinol (Oxf)*. 2024;101:475-484. Epub 2024 Feb 7
8. Ferreira CR, Hackbarth ME, Ziegler SG, Pan KS, Roberts MS, Rosing DR, Whelpley MS, Bryant JC, Macnamara EF, Wang S, Müller K, Hartley IR, Chew EY, Corden TE, Jacobsen CM, Holm IA, Rutsch F, Dikoglu E, Chen MY, Mughal MZ, Levine MA, Gafni RI, Gahl WA. Prospective phenotyping of long-term survivors of generalized arterial calcification of infancy (GACI). *Genet Med* 2021;23:396-407. Epub 2020 Oct 2
9. Rutsch F, Böyer P, Nitschke Y, Ruf N, Lorenz-Depiereux B, Wittkamp T, Weissen-Plenz G, Fischer RJ, Mughal Z, Gregory JW, Davies JH, Lohr C, Strom TM, Schnabel D, Nürnberg P, Terkeltaub R; GACI Study Group. Hypophosphatemia, hyperphosphaturia, and bisphosphonate treatment are associated with survival beyond infancy in generalized arterial calcification of infancy. *Circ Cardiovasc Genet*. 2008;1:133-140.
10. Ferreira CR, Ziegler SG, Gupta A, Groden C, Hsu KS, Gahl WA. Treatment of hypophosphatemic rickets in generalized arterial calcification of infancy (GACI) without worsening of vascular calcification. *Am J Med Genet A*. 2016;170A:1308-1311. Epub 2016 Feb 9
11. Maulding ND, Kavanagh D, Zimmerman K, Coppola G, Carpenter TO, Jue NK, Braddock DT. Genetic pathways disrupted by ENPP1 deficiency provide insight into mechanisms of osteoporosis, osteomalacia, and paradoxical mineralization. *Bone*. 2021;142:115656. Epub 2020 Sep 24
12. Quarles LD. Skeletal secretion of FGF-23 regulates phosphate and vitamin D metabolism. *Nat Rev Endocrinol*. 2012;8:276-286.
13. Höppner J, Kornak U, Sinnigen K, Rutsch F, Oheim R, Grasmann C. Autosomal recessive hypophosphatemic rickets type 2 (ARHR2) due to ENPP1-deficiency. *Bone*. 2021;153:116111. Epub 2021 Jul 9
14. Steichen-Gersdorf E, Lorenz-Depiereux B, Strom TM, Shaw NJ. Early onset hearing loss in autosomal recessive hypophosphatemic rickets caused by loss of function mutation in ENPP1. *J Pediatr Endocrinol Metab*. 2015;28:967-970.
15. Nitschke Y, Baujat G, Botschen U, Wittkamp T, du Moulin M, Stella J, Le Merrer M, Guest G, Lambot K, Tazarourte-Pinturier MF, Chassaing N, Roche O, Feenstra I, Loechner K, Deshpande C, Garber SJ, Chikarmane R, Steinmann B, Shahinyan T, Martorell L, Davies J, Smith WE, Kahler SG, McCulloch M, Wraige E, Loidi L, Höhne W, Martin L, Hadj-Rabia S, Terkeltaub R, Rutsch F. Generalized arterial calcification of infancy and pseudoxanthoma elasticum can be caused by mutations in either ENPP1 or ABCC6. *Am J Hum Genet* 2012;90:25-39. Epub 2011 Dec 29
16. Saito T, Shimizu Y, Hori M, Taguchi M, Igarashi T, Fukumoto S, Fujitab T. A patient with hypophosphatemic rickets and ossification of posterior longitudinal ligament caused by a novel homozygous mutation in ENPP1 gene. *Bone*. 2011;49:913-916. Epub 2011 Jul 2
17. Ralph D, Levine MA, Richard G, Morrow MM, Flynn EK, Uitto J, Li Q. Mutation update: variants of the ENPP1 gene in pathologic calcification, hypophosphatemic rickets, and cutaneous hypopigmentation with punctate keratoderma. *Hum Mutat*. 2022;43:1183-1200. Epub 2022 May 18
18. Ruf N, Uhlenberg B, Terkeltaub R, Nürnberg P, Rutsch F. The mutational spectrum of ENPP1 as arising after the analysis of 23 unrelated patients with generalized arterial calcification of infancy (GACI). *Hum Mutat*. 2005;25:98.
19. Liu ZQ, Chen XB, Song FY, Gao K, Qiu MF, Qian Y, Du M. [Homozygous ectonucleotide pyrophosphatase/phosphodiesterase 1 variants in a girl with hypophosphatemic rickets and literature review]. *Zhonghua Er Ke Za Zhi*. 2017;55:858-861. [in Chinese]
20. Dlamini N, Splitt M, Durkan A, Siddiqui A, Padayachee S, Hobbins S, Rutsch F, Wraige E. Generalized arterial calcification of infancy: phenotypic spectrum among three siblings including one case without obvious arterial calcifications. *Am J Med Genet A*. 2009;149A:456-460.
21. Linglart A, Bioso-Duplan M, Briot K, Chaussain C, Esterle L, Guillaume-Czitrom S, Kamenicky P, Nevoux J, Prié D, Rothenbuhler A, Wicart P, Harvengt P. Therapeutic management of hypophosphatemic rickets from infancy to adulthood. *Endocr Connect*. 2014;3:R13-R30.
22. Boyce AM, Gafni RI, Ferreira CR. Generalized arterial calcification of infancy: new insights, controversies, and approach to management. *Curr Osteoporos Rep*. 2020;18:232-241.
23. Choe Y, Shin CH, Lee YA, Kim MJ, Lee YJ. Case report and review of literature: autosomal recessive hypophosphatemic rickets type 2 caused by a pathogenic variant in ENPP1 gene. *Front Endocrinol (Lausanne)*. 2022;13:911672.
24. Carpenter TO, Whyte MP, Imel EA, Boot AM, Högl W, Linglart A, Padidela R, Van't Hoff W, Mao M, Chen CY, Skrinar A, Kakkis E, San Martin J, Portale AA. Burosumab therapy in children with X-linked hypophosphatemia. *N Engl J Med*. 2018;378:1987-1998.
25. Stern R, Levi DS, Gales B, Rutsch F, Salusky IB. Correspondence on "Prospective phenotyping of long-term survivors of generalized arterial calcification of infancy (GACI)" by Ferreira et al. *Genet Med*. 2021;23:2006-7. Epub 2021 Jun 14
26. Cheng Z, O'Brien K, Howe J, Sullivan C, Schrier D, Lynch A, Jungles S, Sabbagh Y, Thompson D. INZ-701 prevents ectopic tissue calcification and restores bone architecture and growth in ENPP1-deficient mice. *J Bone Miner Res*. 2021;36:1594-1604. Epub 2021 May 5