

## Case Report

### A Novel *SRD5A2* Loss-of-Function Variant in a Chinese Child with 5 $\alpha$ -Reductase type 2 Deficiency

#### Zhou P et al. A *SRD5A2* Variant Caused 5 $\alpha$ -Reductase type 2 Deficiency

Peng Zhou<sup>1,2</sup>, Juanjuan Lyu<sup>1,2</sup>, Xiaomei Sun<sup>1,2</sup>, Ying Liu<sup>1,2</sup>, Chuanjie Yuan<sup>1,2</sup>, Jin Wu<sup>1,2</sup>

<sup>1</sup>Department of Pediatrics, West China Second University Hospital, Sichuan University, Chengdu, China

<sup>2</sup>Key Laboratory of Birth Defects and Related Diseases of Women and Children, Ministry of Education, West China Second University Hospital, Sichuan University, Chengdu, China

#### What has already been known on this topic?

Variants in the *SRD5A2* gene can lead to 5-alpha-reductase type 2 (5 $\alpha$ -RD2) deficiency, a condition categorized under differences/disorders of sex development (DSD). An elevated testosterone (T)/dihydrotestosterone (DHT) ratio following human chorionic gonadotropin (hCG) stimulation is a key diagnostic indicator of 5 $\alpha$ -RD2 deficiency.

#### What this study adds?

This study reports a newly identified compound heterozygous variant in *SRD5A2* that causes 5 $\alpha$ -RD2 deficiency in a Chinese child. The findings expand the spectrum of known *SRD5A2* variants associated with 5 $\alpha$ -RD2 deficiency. Notably, the child presented with atypical external genitalia, including hypertrophy of the labioscrotal folds, which should prompt consideration of DSD in similar cases. The study also underscores the importance of genetic testing, including copy number variation analysis, for accurate diagnosis and genetic counseling in DSD cases.

#### Abstract

Differences or disorders of sex development (DSD) represent a range of congenital conditions that lead to discrepancies among a person's sex chromosomes, gonads, and anatomical sex. Variants in the *SRD5A2* gene can lead to 5-alpha-reductase type 2 (5 $\alpha$ -RD2) deficiency, a condition within the DSD spectrum. Here, we report a case of 5 $\alpha$ -RD2 deficiency in a Chinese child, resulting from a newly identified compound heterozygous variant in *SRD5A2*. The proband, a 2-month-old child assigned female at birth, was initially observed to have bilateral hypertrophy of the labial folds during routine child healthcare visits at a local hospital. An ultrasound scan revealed testicular structures on both sides of the labial folds. The testosterone (T)/dihydrotestosterone (DHT) ratio after stimulation was 37, consistent with 5 $\alpha$ -RD2 deficiency. Whole-exome sequencing and copy number variation analysis identified a novel compound heterozygous variant in *SRD5A2*, consisting of a 175.06 Kb deletion (including exon 1) located at chr2:31802204-31977267 and a c.607G>A (p.G203S) point mutation. Cytogenetic analysis confirmed a 46,XY karyotype. This case highlights a previously unreported compound heterozygous variant in *SRD5A2* associated with 5 $\alpha$ -RD2 deficiency in a Chinese child.

**Keywords:** 5 $\alpha$ -reductase type 2 deficiency, *SRD5A2*, disorders of sex development (DSD), gene deletion

Jin Wu, MD, PhD, Department of Pediatrics, West China Second University Hospital, Sichuan University, No. 20, Section 3, South Renmin Road, Chengdu 610041, China

wangdo620@163.com

27.08.2024

12.12.2024

## Introduction

Differences or disorders of sex development (DSD) are a range of congenital conditions characterized by discrepancies among a person's sex chromosomes, gonads, and anatomical sex. Individuals with DSD who have a 46,XY karyotype are commonly referred to as having 46,XY DSD(1). It is estimated that 7% to 25% of individuals with 46,XY DSD receive a diagnosis with 5 $\alpha$ -RD2 deficiency (2).

Individuals affected by 5 $\alpha$ -RD2 deficiency exhibit a wide spectrum of genital ambiguity, ranging from mild under-virilization in males to completely female external genitalia. Common clinical features include clitoromegaly, hypospadias, micropenis, and cryptorchidism. The severity of these phenotypes is largely determined by the extent of retained SRD5A2 enzyme activity (3). The prevalence of 5 $\alpha$ -RD2 deficiency in the general population remains unknown, but over 180 different variants of the *SRD5A2* gene have been documented so far (3). As genetic analysis becomes more accessible, an increasing number of genetic factors contributing to 5 $\alpha$ -RD2 deficiency are being discovered. In this report, we present a child of Chinese origin with 5 $\alpha$ -RD2 deficiency, in whom genetic analysis revealed a compound heterozygous variant. This included a newly identified 175.06 Kb deletion (encompassing exon 1) located at chr2:31802204-31977267, which was identified as pathogenic, alongside a c.607G>A (p.G203S) variant, also classified as pathogenic in *SRD5A2*.

## Case Report

The proband, a child of Chinese origin, presented at 2 months of age for routine child healthcare evaluation at a local hospital. During the examination, bilateral hypertrophy of the labioscrotal folds was noted. An ultrasound scan performed at that time revealed testicular and epididymal structures on both sides of the labioscrotal folds. The child exhibited no symptoms of vomiting, diarrhea, poor weight gain, or dehydration since birth. Subsequently, the proband was referred to our hospital for further diagnostic evaluation and management.

On physical examination, the child assigned female at birth had a height measured at an SDS of -0.05, and a weight measured at an SDS of 0.91. The proband presented with bilateral hypertrophy of the labial folds. Palpable masses, approximately 1.0 cm  $\times$  0.5 cm  $\times$  0.5 cm in size, were identified on both sides of the labial folds. The clitoris was slightly enlarged, with no visible vaginal opening or pigmentation. The External Genital Masculinization Score (EMS) was assessed as 3 points, with both gonads located in the labial folds (full score 12 points).

Laboratory investigations revealed the following hormone levels: follicle-stimulating hormone (FSH) 2.2 U/L, luteinizing hormone (LH) 3.3 U/L (Reference range: <0.1 U/L), Total testosterone (T) 2.28 ng/ml (Reference range: <0.89 ng/mL), estradiol <11.8 pg/mL, androstenedione 1.61 ng/mL, dehydroepiandrosterone sulfate (DHEAS) 24.40  $\mu$ g/dL, anti-Müllerian hormone (AMH) >18.00 ng/mL, Inhibin B 327.54 pg/mL, adrenocorticotropic hormone (ACTH) 33.00 pg/mL, prolactin 16.4 ng/mL, and progesterone 0.97 ng/mL. Notably, the serum testosterone level was elevated during the mini-puberty phase.

The T/DHT ratio after the human chorionic gonadotropin (hCG) stimulation test was 37, as shown in Table 1, strongly suggesting 5 $\alpha$ -RD2 deficiency. Additional laboratory evaluations, including thyroid function and electrolyte levels, were all within normal ranges.

Ultrasound examination of the labioscrotal folds identified potential testicular tissue measuring 1.4 cm  $\times$  0.6 cm  $\times$  0.7 cm on the right and 1.1 cm  $\times$  0.5 cm  $\times$  0.5 cm on the left. Pelvic magnetic resonance imaging (MRI) revealed abnormal signal nodules in the right labial folds and left inguinal region, with no ovarian, uterine, or vaginal structures observed. Cytogenetic analysis confirmed a 46,XY karyotype, with normal results for the Sex-determining Region Y (SRY) gene and Y chromosome microdeletions.

Whole-exome sequencing and copy number variation analysis conducted on the child and both parents revealed a compound heterozygous variant in the *SRD5A2* gene. The proband inherited the c.607G>A (p.G203S) variant from the mother, while the novel 175.06 Kb deletion (including exon 1) variant located at chr2:31802204-31977267 was inherited from the father, who

carried a slightly smaller 174.9 Kb deletion (including exon 1) located at chr2:31802326-31977379. Based on the guidelines from American College of Medical Genetics and Genomics (ACMG), the c.607G>A (p.G203S) variant was classified as pathogenic with evidence levels PS3\_Supporting+PM1+PM3\_VeryStrong+ PP3, and the novel 175.06 Kb deletion was similarly identified as pathogenic, supported by evidence levels PVS1+PM3+PM2\_Supporting. These findings confirmed the diagnosis of 5 $\alpha$ -RD2 deficiency. Following the final diagnosis of 5 $\alpha$ -RD2 deficiency, the parents expressed a need for time to consider the sex assignment and available treatment options.

### Discussion

5 $\alpha$ -RD2 deficiency was first described in 1974 in studies involving individuals from the Dominican Republic and Dallas, Texas, USA (4,5). The *SRD5A2* gene, which is located on chromosome 2p23, consists of five exons and four introns, with variants identified across all exons. Exons 1 and 4 have been identified as mutation hotspots (3), and exon 3 has also been suggested as a hotspot in studies involving the Turkish population (6,7). In our case, the variant c.607G>A (p.G203S) is located in exon 4, while the novel 175.06 Kb deletion includes exon 1.

This case report describes an infant with female external genitalia and bilateral hypertrophy of the labioscrotal folds, where masses were palpable on both sides of the labioscrotal folds. Ultrasound examination revealed potential testicular tissue in the labioscrotal folds, resulting in a DSD diagnosis. Cytogenetic testing verified a 46,XY karyotype, consistent with a diagnosis of 46,XY DSD. This condition can be broadly categorized into two groups: sex determination disorders marked by abnormal gonadal development, and sex differentiation disorders marked by abnormal production or response to male hormones (8). In this case, the patient exhibited high testosterone levels during mini-puberty, and MRI confirmed the presence of testicles without the presence of ovaries or a uterus, effectively ruling out gonadal dysgenesis and testosterone synthesis disorders. To differentiate 5 $\alpha$ -RD2 deficiency, the hCG test demonstrates higher diagnostic sensitivity than the initial plasma T/DHT ratio. A stimulated T/DHT ratio of  $\geq 8.5$  provides optimal sensitivity for diagnosing this condition during minipuberty(6). Given the elevated T/DHT ratio of 37 following hCG stimulation, 5 $\alpha$ -RD2 deficiency was strongly suspected. Whole-exome sequencing and copy number variation analysis ultimately detected a compound heterozygous variant in *SRD5A2*, including the novel 175.06 Kb deletion (encompassing exon 1) and the c.607G>A (p.G203S) variant, both classified as pathogenic. The final diagnosis of 5 $\alpha$ -RD2 deficiency was thus confirmed.

The 5 $\alpha$ -reductase type 2 enzyme, encoded by *SRD5A2*, is a protein composed of 254 amino acids, featuring an androgen-binding domain at the N-terminal and an NADPH cofactor-binding domain at the C-terminal. This enzyme catalyzes the conversion of testosterone into dihydrotestosterone (DHT), an androgen with greater potency, which is crucial for the proper development of male external genitalia, the prostate, and the urethra (3). Delayed diagnosis of 5 $\alpha$ -RD2 deficiency is common, especially in cases where the phenotype presents as female external genitalia. Early diagnosis is essential for sex of rearing, quality of life, future sexual function and fertility (1). In our case, the proband's atypical genital presentation, including hypertrophy of the labioscrotal folds, warranted suspicion of DSD.

In this patient, the c.607G>A (p.G203S) missense variant was identified as pathogenic based on ACMG guidelines and is known to be associated with reduced enzyme activity, with functional assays showing a 60% reduction in vitro (3). This variant is considered a potential founder mutation within the Chinese cohort (2). The second variant, a novel 175.06 Kb deletion (encompassing exon 1), also classified as pathogenic, has not been previously reported in association with 5 $\alpha$ -RD2 deficiency. A compound heterozygous mutation, involving c.146C>A and a smaller 10 Kb deletion encompassing exon 1, was reported in two siblings with 5 $\alpha$ -RD2 deficiency, who showed female external genitalia along with testes located bilaterally in the inguinal region at birth, consistent with our case (9). However, the deletion identified in our case is significantly larger. This size difference underscores the unique genomic alteration associated with our patient and suggests potential implications for the phenotypic variability observed in 5 $\alpha$ -RD2 deficiency. Our findings highlight the need for further genetic investigations in this condition, which may enhance the understanding of the genotype-phenotype correlation in affected individuals.

While our findings contribute to the expanding spectrum of *SRD5A2* mutations associated with 5 $\alpha$ -RD2 deficiency, this case also highlights the limitations of our current understanding. Functional assays were not conducted to validate the pathogenic potential

of the novel deletion, which represents a limitation of this study. Future research should focus on functional assays to elucidate the specific effects of these variants on enzyme activity and phenotype expression.

### Conclusion

We describe a newly identified compound heterozygous variant in the *SRD5A2* gene, consisting of a 175.06 Kb deletion (including exon 1) and the c.607G>A (p.G203S) variant, in a Chinese child with 5 $\alpha$ -RD2 deficiency. Our case underscores the importance of considering DSD in children presenting with atypical external genitalia, such as hypertrophy of the labioscrotal folds, and highlights the critical role of genetic testing including copy number variation analysis in confirming the diagnosis. Early identification and diagnosis of 5 $\alpha$ -RD2 deficiency are essential for appropriate management and counseling. Our findings contribute to the growing body of evidence regarding the genetic underpinnings of DSD and emphasize the need for further research to understand the functional impact of these variants. Future studies should focus on elucidating the mechanisms by which these genetic alterations affect enzyme function and contribute to the phenotype, ultimately improving the diagnosis and management of 5 $\alpha$ -RD2 deficiency in diverse populations.

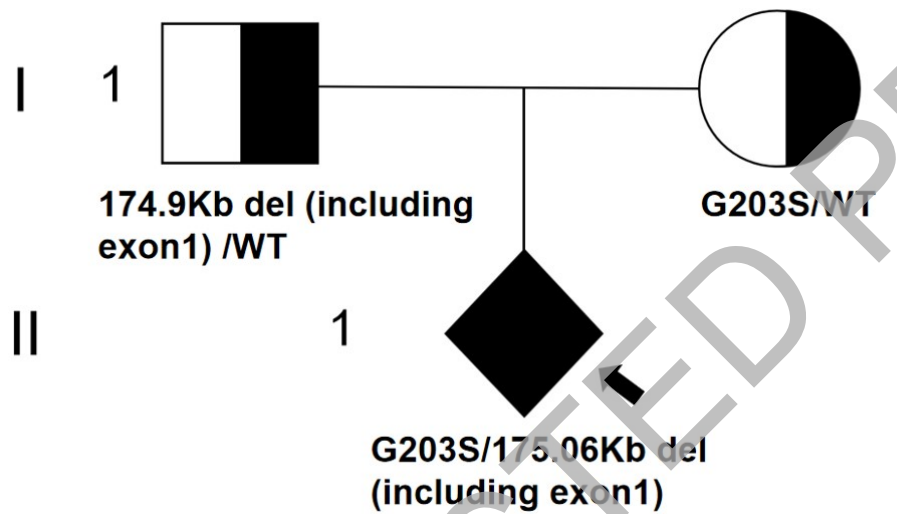
### References

1. Wisniewski A B, Batista R L, Costa E M F, et al. Management of 46, XY differences/disorders of sex development (DSD) throughout life[J]. *Endocrine reviews*, 2019, 40(6): 1547-1572.
2. Gui B, Song Y, Su Z, et al. New insights into 5 $\alpha$ -reductase type 2 deficiency based on a multi-centre study: regional distribution and genotype–phenotype profiling of *SRD5A2* in 190 Chinese patients[J]. *Journal of Medical Genetics*, 2019, 56(10): 685-692.
3. Seo J, Shin S, Kim S, et al. The genotype-phenotype correlation in human 5 $\alpha$ -reductase type 2 deficiency: classified and analyzed from a *SRD5A2* structural perspective[J]. *International journal of molecular sciences*, 2023, 24(4): 3297.
4. Imperato-McGinley J, Guerrero L, Gautier T, et al. Steroid 5 $\alpha$ -reductase deficiency in man: an inherited form of male pseudohermaphroditism[J]. *Science*, 1974, 186(4170): 1213-1215.
5. Walsh P C, Madden J D, Harrod M J, et al. Familial incomplete male pseudohermaphroditism, type 2: decreased dihydrotestosterone formation in pseudovaginal perineoscrotal hypospadias[J]. *New England Journal of Medicine*, 1974, 291(18): 944-949.
6. Abacı A, Çatlı G, Kırbıyık Ö, et al. Genotype–phenotype correlation, gonadal malignancy risk, gender preference, and testosterone/dihydrotestosterone ratio in steroid 5-alpha-reductase type 2 deficiency: a multicenter study from turkey[J]. *Journal of Endocrinological Investigation*, 2019, 42: 453-470.
7. Akcay T, Fernandez-Cancio M, Turan S, et al. AR and *SRD 5A2* gene mutations in a series of 51 Turkish 46, XY DSD children with a clinical diagnosis of androgen insensitivity[J]. *Andrology*, 2014, 2(4): 572-578.
8. Bertelloni S, Tyutyusheva N, Valiani M, et al. Disorders/differences of sex development presenting in the newborn with 46, XY karyotype[J]. *Frontiers in Pediatrics*, 2021, 9: 627281.
9. Kocova M, Plaseska-Karanfilska D, Noveski P, et al. Novel genotype in two siblings with 5- $\alpha$ -reductase 2 deficiency: Different clinical course due to the time of diagnosis[J]. *Balkan Journal of Medical Genetics*, 2019, 22(2): 69-76.

Table 1. Results of the hCG stimulation test

	Pre-hCG	Day-3 post-hCG
Testosterone (pg/mL)	1670	10060
Dihydrotestosterone (pg/mL)	163.00	270.24

Note: hCG, human chorionic gonadotropin



**Figure 1. Pedigree diagram of the family.** Circles represent females, and squares represent males. Half-shaded symbols indicate unaffected heterozygous carriers, and solid symbols represent affected individuals. The proband, subject II-1 (indicated by the arrow), was compound heterozygous for the *SRD5A2* gene, carrying both a novel 175.06 Kb deletion (including exon 1) variant located in chr2:31802204-31977267 and the c.607G>A (p.G203S) variant. The unaffected father (I-1) was heterozygous for a novel 174.9 Kb deletion (including exon 1) variant located in chr2:31802326-31977379, and the unaffected mother (I-2) was heterozygous for the G203S variant.