



DOI: 10.4274/jcrpe.galenos.2025.2024-10-6

J Clin Res Pediatr Endocrinol 2026;18(Suppl 1):70-74

# Atypical Presentation of New Onset Diabetes with Hyperglycemic Hyperosmolar State in Two Toddlers

Alina Haque<sup>1</sup>, Esther E. Bell-Sambataro<sup>2</sup>, Foram Patel<sup>3</sup>, Leena Mamilly<sup>4</sup>, Kathryn Obrynba<sup>4</sup>,  
 Jennifer M. Ladd<sup>4</sup>

<sup>1</sup>The Ohio State University Faculty of Medicine, Columbus, Ohio, United States

<sup>2</sup>Johns Hopkins All Children's Hospital, St. Petersburg, Florida, United States

<sup>3</sup>UT Southwestern Medical Center, Department of Pediatrics, Division of Pediatric Endocrinology, Dallas, Texas, United States

<sup>4</sup>Nationwide Children's Hospital, Department of Pediatrics, Division of Pediatric Endocrinology, Columbus, Ohio, United States

**Cite this article as:** Haque A, Bell-Sambataro EE, Patel F, Mamilly L, Obrynba K, Ladd JM. Atypical presentation of new onset diabetes with hyperglycemic hyperosmolar state in two toddlers. J Clin Res Pediatr Endocrinol. 2026;18(Suppl 1):70-74

## What is already known on this topic?

Hyperglycemic hyperosmolar state (HHS), or mixed HHS with diabetic ketoacidosis (DKA), is a rare complication of diabetes in children. It is most often seen in older children and adolescents and is associated with significant morbidity and mortality.

## What this study adds?

This manuscript highlights two of the youngest patients ever reported with HHS and mixed HHS-DKA at new onset of diabetes. Although rare in toddlers, HHS must be considered upon presentation with severe hyperglycemia. Developmental delay may further increase risk of hyperosmolality given the inability to adequately express thirst and access fluids at younger ages.

## ABSTRACT

Hyperglycemic hyperosmolar state (HHS), or mixed HHS with diabetic ketoacidosis (DKA), is a rare complication of diabetes in children. Prompt recognition of hyperosmolality is necessary to prevent morbidity and mortality. We report two of the youngest cases with HHS, both presenting as new onset of type 1 diabetes. The first was a 3-year-4-month-old male with autism spectrum disorder who presented with glucose 76.0 mmol/L (1370 mg/dL), calculated serum osmolality 388 mOsm/kg, and trace urinary ketones, consistent with HHS and complicated by acute kidney injury. The second was a 4-year-7-month-old male with Trisomy 21 and autism spectrum disorder who presented with glucose 117.3 mmol/L (2114 mg/dL), calculated serum osmolality 401 mOsm/kg, and elevated serum  $\beta$ -hydroxybutyrate, consistent with mixed HHS-DKA and complicated by acute kidney injury and pancreatitis. Both received aggressive rehydration although hyperosmolality was initially overlooked,

**Corresponding Author:** Jennifer M. Ladd, MD, MSc, Nationwide Children's Hospital, Department of Pediatrics, Division of Pediatric Endocrinology, Columbus, Ohio, United States

**E-mail:** jennifer.ladd@nationwidechildrens.org **ORCID:** orcid.org/0009-0005-1949-4367

**Conflict of interest:** None declared

**Received:** 20.12.2024 **Accepted:** 12.02.2025 **Epub:** 08.05.2025 **Publication Date:** 22.05.2026



© Copyright 2026 by Turkish Society for Pediatric Endocrinology and Diabetes / The Journal of Clinical Research in Pediatric Endocrinology published by Galenos Publishing House. Licensed under a Creative Commons Attribution-NonCommercial-NoDerivatives 4.0 (CC BY-NC-ND) International License.

resulting in earlier and higher insulin dosing more typical of DKA than HHS. Both recovered without sequelae. In each case, young age and developmental delay likely contributed to hyperosmolality, given the inability to communicate increased thirst and freely access water. A high index of suspicion for HHS is necessary as significant rehydration and delayed start of low dose insulin infusion are recommended to prevent complications.

**Keywords:** Developmental delay, hyperglycemic hyperosmolar state, pediatrics, type 1 diabetes

## Introduction

New onset diabetes mellitus in young children can initially go unrecognized given the inability to verbalize symptoms such as thirst, lack of free access to fluids, and lack of toilet training, which can mask urinary frequency. As a result, young children have the highest prevalence of diabetic ketoacidosis (DKA) at presentation of new onset diabetes, with 46.7% of children aged 0-4 years presenting in DKA in the SEARCH for Diabetes in Youth Study including over 7,000 children in the United States (1,2). Hyperglycemic hyperosmolar state (HHS), another complication of diabetes with more severe hyperglycemia and dehydration, has less frequently been reported in children, with one single center study of 390 youth aged 0-21 years showing only 0.8% presenting in HHS and 13.8% presenting in mixed HHS-DKA (3).

Prompt distinction between HHS and DKA, and identification of mixed states, is critical given that different treatment considerations are applied for each entity and given the higher rates of morbidity and mortality in HHS or mixed HHS-DKA compared to DKA alone (4,5). Herein, we present two of the youngest reported cases of toddlers presenting with new onset diabetes with hyperosmolality. Understanding the distinctive features of these cases can facilitate earlier recognition of HHS and mixed HHS-DKA in very young children and thus guide earlier appropriate treatment to minimize complications.

## Case Report

### Case 1

A 3-year-4-month-old nonverbal male with autism spectrum disorder presented to an outside hospital emergency department with fatigue and decreased activity level. On the day of presentation, he had one episode of emesis as well as heavy breathing. He was not on daily medications. Initial vital signs were significant for tachycardia [140 beats per minute (bpm)] and hypoxia [oxygen saturation ( $SpO_2$ ) as low as 78%] with respiratory rate of 20 breaths per minute. Physical examination revealed decreased responsiveness, sunken eyes, and dry oral mucosa, although lungs were clear to auscultation. Initial laboratory investigation showed severely elevated serum glucose of 76.0 mmol/L (1370 mg/dL) with measured hyponatremia of 149 mmol/L (corrected sodium 169 mmol/L) and calculated serum osmolality 388 mOsm/kg. Venous blood gas was without acidosis (pH 7.40,  $pCO_2$  31 mmHg, and bicarbonate 19 mmol/L),

and urinary ketones were trace. Hemoglobin A1c (HbA1c) was 72 mmol/mol (8.7%) (Table 1). Respiratory viral antigen testing was positive for parainfluenza. Upon further discussion, parents noted increased urine output and increased intake of PediaSure® and 2% milk over the preceding three days.

The patient was started on supplemental oxygen via nasal cannula. Initial resuscitation consisted of a 20 mL/kg normal saline bolus given over one hour and followed by a second 20 mL/kg normal saline bolus one hour after initial bolus. This was followed by isotonic intravenous (IV) fluids at 1.5 times maintenance rate. Additional results were consistent with acute kidney injury [initial creatinine 61.9 mmol/L (0.7 mg/dL)]. IV insulin infusion was started at 0.1 units/kg/hr, and the patient was transferred to our emergency department.

On arrival at our hospital, point-of-care blood glucose was 15.2 mmol/L (273 mg/dL). Given this rapid decline in blood glucose level, and given that it was then recognized that the initial presentation was consistent with HHS rather than DKA, the insulin drip was temporarily paused while IV rehydration with isotonic fluids was increased to twice maintenance rate. Upon stabilization of serum glucose, the IV insulin drip was resumed at 0.025 units/kg/hr and continued until transition to subcutaneous insulin 12 hours after presentation (Figure 1). Serum creatinine normalized with rehydration. He was monitored for development of rhabdomyolysis and pancreatitis; serum creatinine kinase and lipase remained normal throughout the hospitalization. He did not have any clinical evidence of cerebral edema or venous thrombosis.

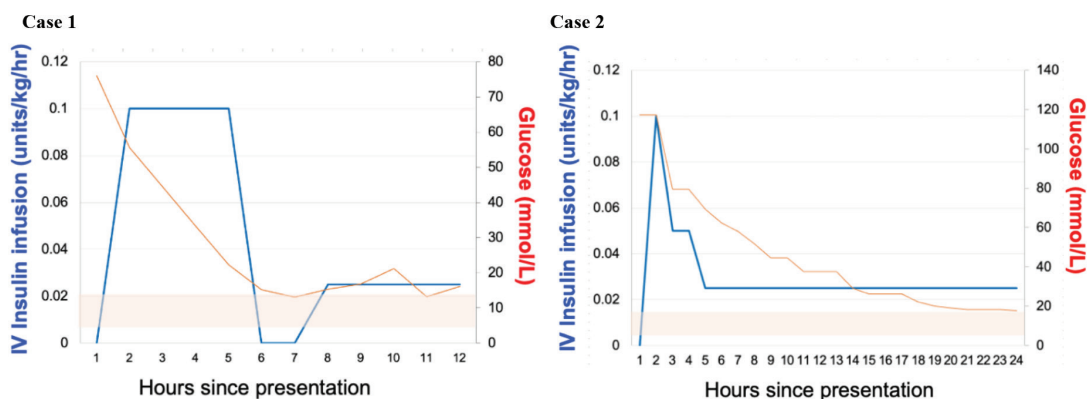
At the time of discharge, he required a total daily dose of 0.4 units/kg/day of basal-bolus subcutaneous insulin. Islet antigen 2 antibody and anti-insulin antibodies were positive, consistent with a diagnosis of type 1 diabetes.

### Case 2

A 4-year-7-month-old nonverbal male with Trisomy 21, autism spectrum disorder, duodenal atresia status post repair, cholestasis, and bilateral cystic kidney disease presented to our emergency department with lethargy and respiratory distress. Daily medications included prophylactic sulfamethoxazole-trimethoprim, ursodiol, and polyethylene glycol. Initial vital signs were notable for tachycardia (heart rate 144 bpm), but no tachypnea (respiratory rate 18 breaths per minute) or hypoxia

Table 1. Initial laboratory values at presentation			
	Case 1	Case 2	Reference range
Serum glucose	76.0 (1370)	117.3 (2114)	3.3-6.4 mmol/L (60-115 mg/dL)
Venous pH	7.40	7.15	7.32-7.42
pCO <sub>2</sub>	31	50	33-46 mmHg
Bicarbonate	19	19	21-30 mmol/L
Measured sodium	149	134	135-145 mmol/L
Corrected sodium <sup>a</sup>	169	166	135-145 mmol/L
Calculated serum osmolality <sup>b</sup>	388	401	271-296 mOsm/kg
Serum βhydroxybutyrate <sup>c</sup>	--	4.4	<0.3 mmol/L
Hemoglobin A1c	72 (8.7)	89 (10.3)	20-38 mmol/mol (4.0-5.6%)
Creatinine	61.9 (0.7)	123.8 (1.4)	17.7-35.4 mmol/L (0.2-0.4 mg/dL)
Lipase	4	7740	<202 U/L

<sup>a</sup>Corrected sodium calculated as 1.6\*(serum glucose in mg/dL-100)/100+measured sodium,  
<sup>b</sup>Calculated serum osmolality as 2\*measured sodium+serum glucose in mg/dL/18+BUN/2.8,  
<sup>c</sup>Serum βhydroxybutyrate not measured at presentation in Case 1; urinary ketones were trace at presentation in Case 1.  
 BUN: blood urea nitrogen



**Figure 1.** Trends of blood glucose decline and IV insulin dosing  
 Note: Blue lines show IV insulin infusion rates. Red lines show blood glucose levels, with shaded red area representing target blood glucose range [5.6-11.1 mmol/L (100-200 mg/dL)] while on insulin infusion  
 IV: intravenous

(SpO<sub>2</sub> 97%). Physical examination revealed somnolence, dry oral mucosa, clear lungs, and a diffusely tender abdomen. Initial laboratory testing revealed markedly elevated serum glucose of 117.3 mmol/L (2114 mg/dL) with hypernatremia (measured sodium 134 mmol/L with corrected sodium 166 mmol/L). Venous blood gas was consistent with a predominant respiratory acidosis (pH 7.15, pCO<sub>2</sub> 50 mmHg, and bicarbonate 19 mmol/L), and serum β-hydroxybutyrate was elevated at 4.4 mmol/L. Calculated serum osmolality at presentation was 401 mOsm/kg. HbA1c was 89 mmol/mol (10.3%) (Table 1). Chest X-ray was unremarkable, and all infectious testing was negative. Upon more detailed history, parents noted polyuria over the prior week and had offered water and diluted juice.

The patient was started on bilevel positive airway pressure due to initial hypercapnia and respiratory distress. Initial resuscitation consisted of a total of two 20 mL/kg normal saline boluses, each given over one hour sequentially, followed by isotonic IV fluids at twice maintenance rate. IV insulin infusion was initially started at 0.1 units/kg/hr, but was soon thereafter decreased to 0.025 units/kg/hr given later recognition that initial evaluation was consistent with mixed HHS-DKA, as well as a component of respiratory acidosis (Figure 1). Additional results were consistent with pancreatitis (initial serum lipase 7740 U/L in the context of diffuse abdominal pain), which may have contributed to the respiratory acidosis on presentation. Laboratory testing also showed acute kidney injury [initial creatinine 123.8 mmol/L (1.4 mg/dL)]. IV insulin infusion was

continued at 0.025 units/kg/hr for 36 hours until resolution of pancreatitis, normalization of sodium, and clinical improvement occurred. Serum creatinine normalized with rehydration, and serial creatine kinase levels remained normal without evidence of rhabdomyolysis. He did not have signs of cerebral edema clinically or on head computed tomography. No physical signs of venous thrombosis were present. After transition from IV insulin to subcutaneous insulin, he was noted to have marked insulin resistance, requiring a total daily dose of 1.7 units/kg/day of basal-bolus subcutaneous insulin on discharge from the hospital.

Further work-up revealed negative pancreatic autoantibodies including glutamic acid decarboxylase-65, islet antigen 2, anti-insulin, and zinc transporter 8. A monogenetic diabetes panel of 18 genes including *HNF1 $\beta$*  was obtained due to negative autoantibodies and history of renal cysts; the panel was negative for any mutations. He is therefore currently managed as having antibody negative type 1 diabetes in the setting of Trisomy 21. Now 1.5 years after diagnosis, he is requiring a more typical 0.7 units/kg/day of insulin through an automated insulin delivery system, with his most recent HbA1c of 52 mmol/mol (6.9%).

## Discussion

The two cases described herein represent two of the youngest reported patients with HHS in the literature (6,7,8,9,10). The first case had a more classical presentation of HHS with minimal ketosis and without acidosis, whereas the second case had mixed features of both HHS and DKA. Both patients received significant fluid resuscitation on arrival given clinical evidence of dehydration, but the features of hyperosmolality and HHS were not immediately recognized in such young and developmentally delayed patients. Given positive autoantibodies in the first patient and negative genetic testing in the second patient, both toddlers were presumed to have new onset type 1 diabetes.

Although DKA has often been thought to be associated with type 1 diabetes and HHS with type 2 diabetes, either form of diabetes can present with DKA, HHS, or a mixed picture. The diagnosis of HHS, or mixed HHS-DKA, in a young child therefore requires a high index of suspicion and is of critical importance due to its implications for prognosis, management, and complications (11,12). Both HHS and DKA present with hyperglycemia, but differ in pathophysiology and risk of complications, leading to differences in initial management. In DKA, there is an absolute paucity of insulin production, resulting in hyperglycemia and ketone production through lipolysis. The diagnostic criteria for DKA include a serum glucose concentration greater than 11.1 mmol/L (200 mg/dL), metabolic acidosis with a venous pH

less than 7.3 or serum bicarbonate less than 18 mmol/L, and ketonemia (serum  $\beta$ -hydroxybutyrate greater than 3 mmol/L or moderate-to-large urine ketones) (11). Conversely, in HHS, increased gluconeogenesis and glycogenolysis occur, resulting in very high serum glucose levels, but the body maintains enough circulating insulin to prevent ketone formation (5). The diagnostic criteria of HHS include a serum glucose concentration greater than 33.3 mmol/L (600 mg/dL), serum osmolality greater than 320 mOsm/kg, and absence of significant ketosis and acidosis (11). Presentation can also be mixed, meeting criteria for both HHS and DKA. HHS is most often described in older children and adolescents and is exceedingly rare in younger children, with an incidence rate of 3.2 per 1,000,000 children in 2009 in a large hospital discharge database in the United States (13).

The distinction between HHS and DKA, and the prompt recognition of the presence of each, is crucial for appropriate treatment. The total body fluid deficit in HHS is more severe than in DKA, but this may not always be clinically appreciated as hypertonicity relatively preserves intravascular volume (14). Therefore, more aggressive fluid resuscitation is required in HHS than in DKA to prevent circulatory collapse and maintain intravascular volume as hypertonicity declines, thereby allowing fluids to move to the extravascular space (14). For this reason, unlike in DKA, insulin infusion in HHS should be delayed until adequate initial volume resuscitation has been achieved and serum glucose is no longer declining with hydration alone, although earlier insulin administration can be considered in mixed HHS-DKA (11,14). Lower rates of insulin infusion may also be needed to prevent a rapid decline in blood glucose levels which may contribute to large fluid shifts (14). In both cases presented here, IV insulin infusions were initially started at rates more typical for DKA after primary resuscitation. In the first case, the insulin infusion was halted upon recognition of significant hyperosmolality with minimal ketosis and then restarted at a much lower dose to prevent continued rapid decline in blood glucose. In the second case of mixed HHS-DKA, earlier insulin administration was likely appropriate given ketosis, although the rate was decreased to again preserve a slower decline in blood glucose.

In addition to more pronounced electrolyte imbalances, other complications are more likely to be present in HHS than in DKA including rhabdomyolysis, pancreatitis, venous thrombosis, acute kidney injury, and malignant hyperthermia, all of which can contribute to morbidity and likely account for the 10-fold higher mortality in HHS or mixed HHS-DKA than in DKA alone (4,5,12,14). Although both cases here had acute kidney injury at presentation and the second case also had evidence of pancreatitis, neither patient developed rhabdomyolysis, venous thrombosis, cerebral edema, or circulatory collapse.

In both cases, young age and developmental delay likely contributed to marked hyperglycemia and hyperosmolality, as well as overt dehydration, at presentation. Both patients were non-verbal, leading to the inability to clearly communicate increased thirst, and given their young ages, neither were able to freely access water. Both toddlers were also inadvertently provided high carbohydrate-containing liquids (including diluted juice and PediaSure®), which likely exacerbated the severe underlying hyperglycemia. Developmental delay has been reported to be a contributor to presentation of HHS in published case reports, although these children were all older (7,10). In a single center study of 390 youth presenting with diabetes, those with intellectual disability, including developmental delay, were also found to have 3.4 higher odds of hyperosmolality compared to those without this disability (3). Thus, increased awareness of the potential for HHS, or mixed HHS-DKA, upon presentation with new onset diabetes in those with developmental delay, including at very young ages, is necessary to reduce the likelihood of delayed treatment and complications.

## Conclusion

We have highlighted two cases, one of HHS and one of mixed HHS-DKA in toddlers, an age group in which hyperosmolality is rare. Providers should have a high index of suspicion for HHS and mixed HHS-DKA in young patients who present with a glucose greater than 33.3 mmol/L (600 mg/dL), given the differing management considerations and complications in HHS as compared to DKA alone. This suspicion should be heightened in those with developmental delay, given the increased risk of hyperosmolality and delayed recognition of symptoms. Prompt management of HHS with aggressive fluid resuscitation and delayed start of low dose insulin infusion is recommended.

### Ethics

**Informed Consent:** Consent was obtained from the patient's parents.

### Footnotes

**Prior Presentations:** The second case was presented as a peer-reviewed abstract at the Canadian Pediatric Endocrine Group 2023 annual meeting and the Pediatric Endocrine Society 2023 annual meeting.

### Authorship Contributions

Concept: Esther E. Bell-Sambataro, Foram Patel, Leena Mamilly, Kathryn Obrynba, Jennifer M. Ladd, Design: Esther E. Bell-Sambataro, Foram Patel, Leena Mamilly, Kathryn Obrynba, Jennifer M. Ladd, Data Collection or Processing: Esther E. Bell-Sambataro, Foram Patel, Leena Mamilly, Kathryn Obrynba, Jennifer M. Ladd, Literature Search: Alina Haque, Esther E. Bell-Sambataro, Foram Patel, Leena Mamilly, Jennifer M. Ladd, Writing: Alina Haque, Esther E. Bell-Sambataro, Foram Patel, Leena Mamilly, Kathryn

Obrynba, Jennifer M. Ladd.

**Financial Disclosure:** The authors declared that this study received no financial support.

## References

1. Jensen ET, Stafford JM, Saydah S, D'Agostino RB, Dolan LM, Lawrence JM, Marcovina S, Mayer-Davis EJ, Pihoker C, Rewers A, Dabelea D. Increase in prevalence of diabetic ketoacidosis at diagnosis among youth with type 1 diabetes: The SEARCH for diabetes in youth study. *Diabetes Care*. 2021;44:1573-1578. Epub 2021 Jun 7
2. Alonso GT, Coakley A, Pyle L, Manseau K, Thomas S, Rewers A. Diabetic ketoacidosis at diagnosis of type 1 diabetes in Colorado children, 2010-2017. *Diabetes Care*. 2020;43:117-121. Epub 2019 Oct 10
3. Agrawal S, Baird GL, Quintos JB, Reinert SE, Gopalakrishnan G, Boney CM, Topor LS. Pediatric diabetic ketoacidosis with hyperosmolality: clinical characteristics and outcomes. *Endocr Pract*. 2018;24:726-732. Epub 2018 Aug 7
4. Simon R, Shah A, Shah B. Hyperosmolar nonketotic hyperglycemia. *Pediatr Rev*. 2024;45:169-171.
5. Pasquel FJ, Umpierrez GE. Hyperosmolar hyperglycemic state: a historic review of the clinical presentation, diagnosis, and treatment. *Diabetes Care*. 2014;37:3124-3131.
6. Cho YM, Park BS, Kang MJ. A case report of hyperosmolar hyperglycemic state in a 7-year-old child: an unusual presentation of first appearance of type 1 diabetes mellitus. *Medicine (Baltimore)*. 2017;96:e7369.
7. Butorac Ahel I, Severinski S, Lah Tomulic K, Milardovic A, Baraba Dekanic K, Palcevski D. An extremely high blood glucose level in a child with hyperglycemic hyperosmolar state and type 1 diabetes. *J Pediatr Endocrinol Metab*. 2021;34:1045-1048.
8. Alharfi IM, Singh R, Clarson C, Foster JR. Hyperosmolar hyperglycemic state without ketosis in a toddler with type 1 diabetes. *Pediatr Emerg Care*. 2014;30:485-487.
9. Goldman SL. Hyperglycemic hyperosmolar coma in a 9-month-old child. *Am J Dis Child*. 1979;133:181-183.
10. Parra Villasmil MG, Patel S, Tansey M, Badheka A, Chegondi M. A Rare presentation of new-onset type 1 diabetes mellitus in a developmentally delayed child with an overlap of diabetic ketoacidosis and hyperglycemic hyperosmolar state. *Cureus*. 2022;14:e28983.
11. Glaser N, Fritsch M, Priyambada L, Rewers A, Cherubini V, Estrada S, Wolfsdorf JI, Codner E. ISPAD clinical practice consensus guidelines 2022: Diabetic ketoacidosis and hyperglycemic hyperosmolar state. *Pediatr Diabetes*. 2022;23:835-856.
12. Zarse E, Knoll MM, Halpin K, Thompson M, Williams DD, Tallon EM, Kallanagowdar G, Tsai S. Recognizing complications in youth with diabetes admitted with diabetic ketoacidosis versus hyperglycemic hyperosmolar state. *J Pediatr Health Care*. 2024;38:761-768. Epub 2024 Jun 18
13. Bagdure D, Rewers A, Campagna E, Sills MR. Epidemiology of hyperglycemic hyperosmolar syndrome in children hospitalized in USA. *Pediatr Diabetes*. 2013;14:18-24. Epub 2012 Aug 28
14. Zeitler P, Haqq A, Rosenbloom A, Glaser N; Drugs and Therapeutics Committee of the Lawson Wilkins Pediatric Endocrine Society. Hyperglycemic hyperosmolar syndrome in children: pathophysiological considerations and suggested guidelines for treatment. *J Pediatr*. 2011;158:9-14. Epub 2010 Oct 30