



DOI: 10.4274/jcrpe.galenos.2025.2025-8-11
J Clin Res Pediatr Endocrinol 2026;18(2):282-287

Mucopolysaccharidosis or Skeletal Dysplasia? Clinical and Radiologic Clues for Differential Diagnosis Based on Difficult Cases

✉ Ayşe Akyüz¹, ✉ Hakan Atalar², ✉ Kübra Çilesiz¹, ✉ Aslı İnci¹, ✉ İlyas Okur¹, ✉ Leyla Tümer¹, ✉ Fatih Ezgü^{1,3}

¹Gazi University Faculty of Medicine, Department of Pediatrics, Department of Inborn Metabolic Diseases, Ankara, Türkiye

²Gazi University Faculty of Medicine, Department of Orthopedics and Traumatology, Ankara, Türkiye

³Gazi University Faculty of Medicine, Department of Pediatrics, Department of Pediatric Genetics, Ankara, Türkiye

Cite this article as: Akyüz A, Atalar H, Çilesiz K, İnci A, Okur İ, Tümer L, Ezgü F. Mucopolysaccharidosis or skeletal dysplasia? Clinical and radiologic clues for differential diagnosis based on difficult cases. J Clin Res Pediatr Endocrinol. 2026;18(2):282-287

ABSTRACT

Objective: The skeletal abnormalities of mucopolysaccharidosis (MPS) and skeletal dysplasia (SD) may be similar and even indistinguishable. This study aims to elucidate clinical clues and overlapping features that may assist in the different diagnosis.

Methods: The clinical features of patients who were first referred to endocrinology or rheumatology department for short stature or joint abnormalities were addressed and signs were examined upon different diagnosis.

Results: Three patients (I, II and III) were diagnosed with SD with overlapping and also distinguishing skeletal features compared with MPS. An atypical presentation defined in patient IV who was diagnosed with Morquio syndrome. Patients V and VI were diagnosed with MPS with early onset and typical skeletal features accompanied with additional systemic manifestations uncommon in SD.

Conclusion: In conclusion, this study emphasizes the clinical and radiological evaluation and nuances distinctions in clinical presentations that will highlight the challenges and guide to distinguishing different diagnosis of MPS and SD in atypical presentations for achieving the accurate diagnosis.

Keywords: Mucopolysaccharidosis, skeletal dysplasia, orthopedics, radiology, genetics

What is already known on this topic?

Mucopolysaccharidosis and skeletal dysplasia are genetic bone disorders mostly presented by short stature and joint abnormalities. Clinical and radiological assessments consist the main steps for diagnosis.

Corresponding Author: Ayşe Akyüz, Gazi University Faculty of Medicine, Department of Pediatrics, Department of Inborn Metabolic Diseases, Ankara, Türkiye

E-mail: aysheakyz@gmail.com **ORCID:** orcid.org/0000-0002-0647-3138

Conflict of interest: None declared

Received: 28.08.2025 **Accepted:** 23.11.2025 **Epub:** 04.12.2025 **Publication Date:** 01.07.2026



©Copyright 2026 by Turkish Society for Pediatric Endocrinology and Diabetes / The Journal of Clinical Research in Pediatric Endocrinology published by Galenos Publishing House. Licensed under a Creative Commons Attribution-NonCommercial-NoDerivatives 4.0 (CC BY-NC-ND) International License.

What this study adds?

This study highlights the clinical and radiological clues for distinguishing different diagnosis in patients with short stature or joint abnormalities for accurate diagnosis even in atypical presentations.

Introduction

Mucopolysaccharidoses (MPS) are a group of inborn metabolic diseases caused by mutations in genes encoding lysosomal hydrolases required for degradation of mucopolysaccharides, resulting in skeletal abnormalities described as dysostosis multiplex (1,2). Skeletal dysplasias (SD) are a group of genetic disorders characterized by short stature, bone and cartilage abnormalities. Common pathogeneses leading to similar clinical manifestations have been classified into different SD groups (3).

Some overlapping signs and symptoms of both disease groups make the correct diagnosis difficult and often lead to diagnostic delay (4). Currently, the use of gene panels including both *MPS* and *SD* genes has become widespread for distinguishing differential diagnoses in patients with short stature and skeletal manifestations (5). However, appropriate and detailed clinical and radiological assessment can provide more accurate and rapid guidance. The distinguishing clinical and radiological criteria for these two groups of disorders are illustrated in this report through the presentation of illustrative patient examples.

Methods

Six patients, three with SD and three with MPS were enrolled in the study. Patients who were initially referred to the endocrinology or rheumatology department due to short stature or joint anomalies and were followed up by these departments with other diagnoses were included in the study to address the difficulty of differential diagnosis. In addition, two patients who were initially referred to other departments despite having distinct features of MPS were included to underline the overlapping clinical symptoms. Patients I, II, III, V and VI were first referred to the endocrinology department, but patient IV first attended the rheumatology department.

All patients had final diagnosis and follow-up as MPS or SD in Departments of Inborn Metabolic Disease and Pediatric Genetic between 2010 and 2024. Symptoms leading to referral, medical history, radiological assessment, enzyme activity analysis results and molecular analysis results were obtained from the patients' medical records. This study was performed in line with the principles of the Declaration of Helsinki. Ethical approval was granted by the Ethics Committee of Gazi University (approval no.: 12, date: 09.07.2024). Informed consent forms were

obtained from patients or their parents. No statistical analysis was performed.

Results

Patients' demographic data, genotypes, clinical and radiological assessments are listed in Table 1. Patients' radiological abnormalities are presented in Figure 1.

Discussion

Recognizing distinguishing clues from radiological findings is the first step to establish the diagnosis of SD or MPS. The clinical picture of MPS and SD may vary by disease severity and atypical presentations are not unusual (6).

As in our cases, one of the most common presentations of MPS and SD was short stature. Several patients with short stature were first admitted to the pediatric endocrinology department. Careful family history and family growth patterns constitute the first step for evaluating constitutional delay or familial short stature, both with near-normal growth velocity during childhood, in contrast to both MPS or SD. In addition to laboratory tests for primary endocrinopathies, detailed physical examination plays a key role in recognizing genetic disorders presenting with short stature (7). Facial dysmorphism is more frequently observed in MPS and is often noted during the initial assessment, but may also be associated with SD as in Patients I and II (8). In the diagnostic algorithm for short stature, radiological assessment is not routinely recommended. However, skeletal survey should be performed especially in the presence of disproportionate short stature or short stature associated with facial dysmorphism or any skeletal deformities (7,9). Short stature with a short trunk is a common finding in MPS due to severe spinal involvement but atypical cases, such as patient IV, may present with normal proportions without short trunk. Furthermore, achievement of normal growth may be seen in attenuated forms of MPS, thus normal height for age should not exclude MPS (10).

Another common manifestation of attenuated types of MPS is joint stiffness and contractures. Those clinical findings are prominent in rheumatologic diseases, such as rheumatoid arthritis. It has been suggested that patients with joint involvement, particularly affecting the hands should be screened for MPS I. Moreover, MPS must be considered in the differential diagnosis of rheumatoid arthritis, especially when morning stiffness, elevated erythrocyte sedimentation rate or

Table 1. Patients' demographic data, genotypes, clinical and radiological assessments						
Patients	I	II	III	IV	V	VI
Gender	F	M	M	M	F	F
Age at diagnosis	14 y	2 y	14 m	17 y	18 m	20 m
Diagnosis	SEMD	SEMD	SED	MPS IVA	MPS IVA	MPS I
Enzyme activity/ genotype (nucleotide change)	TONSL Compound heterozygous c.122-4_126del (LP: PV51, PM2) and c.344G>A (VUS: PM2) ^a	COL2A1 Homozygous c.1339G>C (LP: PM1, PP2, PM2, PM5, PP3) ^a	ACAN Homozygous c.548C>T (VUS: PM2) ^a	N-Acetylgalactosamine 6-sulphatase <0.1 nmol/h/ prot (1.53-10.6) ^b GALNS Homozygous c.1249 G>T (VUS: PM2, PP2) ^a	N-Acetylgalactosamine 6-sulphatase <0.1 nmol/h/prot (1.53- 10.6) ^b	Alpha-iduronidase :2.27 nmol/h/ mg protein (19-41)
Parental consanguinity	No	Yes	No	No	Yes	No
Symptoms at referral	Short stature skeletal deformities	Short stature skeletal deformities	Short stature macrocephaly	Short stature joint pain	Short stature	Spine deformities hepatosplenomegaly
Physical examination	Short stature (Height SDS: -8.1) Depressed nasal bridge Bulbous nose Prognathism Frontal bossing Scoliosis Increased lumbar lordosis Genu valgum	Short stature (Height SDS: -3.2) Depressed nasal bridge Frontal bossing Pectus excavatum Short limbs Genu varum	Short Stature (Height SDS: -2.0) Coarse face Acquired Macrocephaly Brachydactyly Proximal shortness of limbs	Short stature (Height SDS: -2.3) Pectus Carinatum Genu varum Broad joints of his hands and limitation of extension at all joints	Short stature (Height SDS: -2.1) Joint laxity Genu valgum	Short stature (Height SDS: -2.0) Coarse face Acquired Macrocephaly Prominent metopic suture Pectus carinatum Thoracal kyphosis Splint for hip dysplasia Brachydactyly Large Mongolian spot
Additional condition	No	No	No	Diagnosed as JRA and FMF Treated with etanercept	No	Adenoid hypertrophy and recurrent low respiratory tract infection Motor development delay
Radiological assessment at diagnosis	J-shaped sella Kyphoscoliosis Biconcave vertebral bodies Decreased interpeduncular distance Osteopenia Flattened capital femoral epiphysis Broadening of ribs at sternal ends	Kyphoscoliosis Increased lumbar lordosis Platyspondyly Ovoid configuration and irregular vertebral endplates Metaphyseal and proximal femoral epiphysial irregularities	J-shaped sella Irregular vertebral endplates Ovoid configuration and beaking of vertebral bodies Epiphysial irregularity in distal femur	Thickened skull Oar-shaped ribs Epiphyseal and metaphyseal irregularities of proximal femur Deformities in vertebral endplates	Kyphosis Genu valgum Vertebral beaking Platyspondyly Oar-shaped ribs Round shaped iliac bone Coxa valga Irregular acetabular border and femoral head	J-shaped sella Thoracolumbar kyphosis Oar-shaped ribs Posterior scalloping and inferior beaking of vertebral bodies Round shaped iliac bones Coxa valga Bullet-shaped metacarpal bones

^aPatients were performed exome sequencing ^bMultiple sulfatase deficiency was excluded
y: years, m: months, SEMD: spondyloepiphyseal dysplasia, JRA: juvenil rheumatoid arthritis, FMF: Familial Mediterranean Fever, LP: likely pathogenic VUS; Variant of uncertain
significance upon ACMG classification, PV51: Pathogenic very strong (null variant), PM2: extremely low frequency in gnomAD population databases, PM1: Non-truncating non-synonymous variant is located in a mutational
hot spot, PP2: Missense variant in a gene with low rate of benign missense mutations, PM5: Different amino acid change as a known pathogenic variant, PP3: For a missense or a splicing region variant, computational
prediction tools unanimously support a deleterious effect on the gene

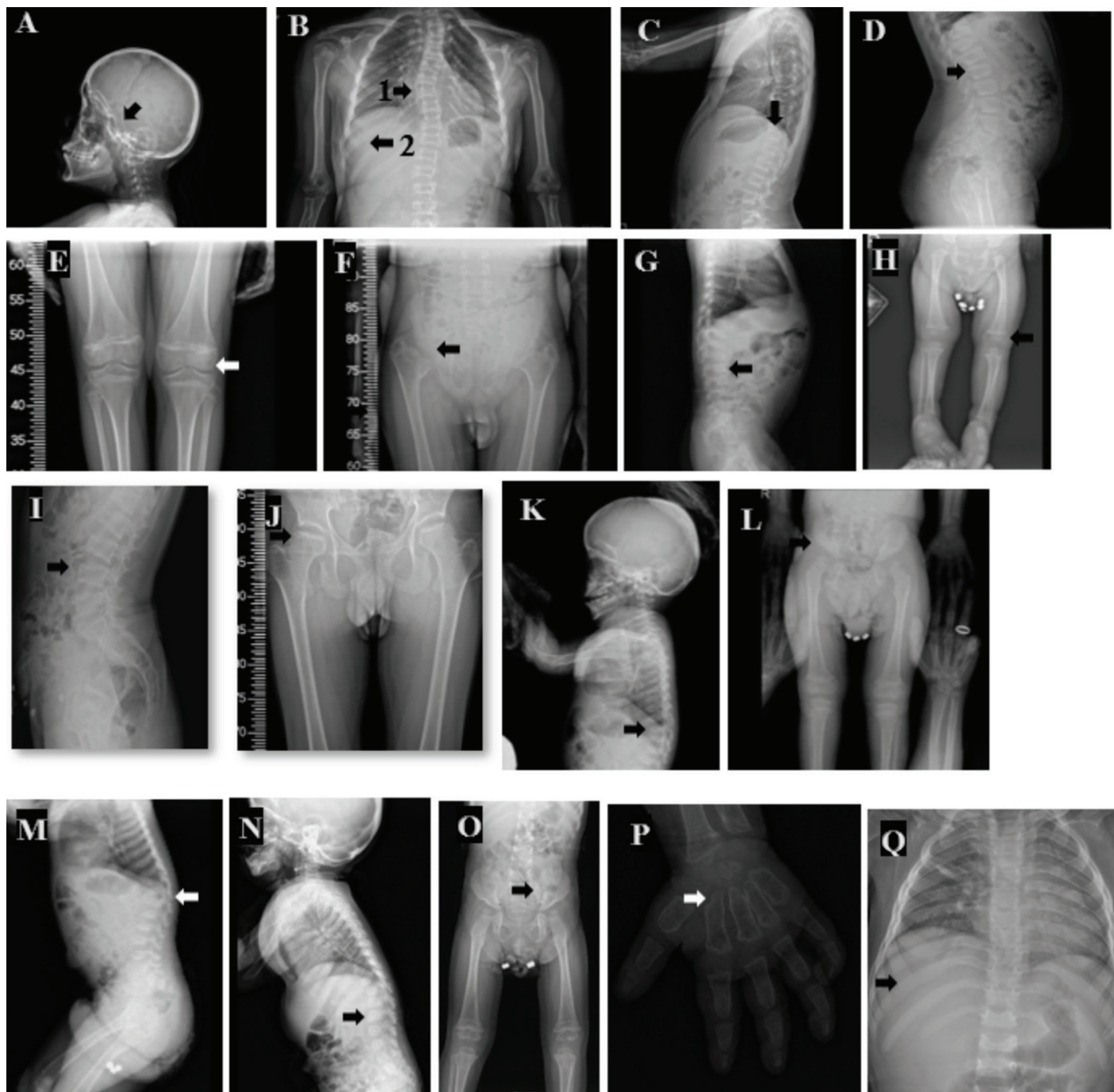


Figure 1. Patients' radiological abnormalities. **A)** J-shaped sella of P1, **B)** Scoliosis (1), broadening of ribs at the sternal ends (2) of P1 **C)** Biconcave vertebral bodies of P1. **D)** Platypondyly, ovoid configuration and irregular vertebral endplates of P2. **E)** Metaphyseal irregularities of P2 **F)** Delayed epiphysal ossification/ Irregular borders of femoral head and acetabulum of P2 **G)** Ovoid configuration and beaking of vertebral bodies of P3 **H)** Epiphysal irregularity of P3 **I)** Irregularities in vertebral endplates of P4 **J)** Epimetaphyseal irregularities of proximal femur of P4. **K)** Anterior beaking in vertebral bodies, platyspondyly of P5 **L)** Round shaped iliac bone, coxa valga, irregular acetabular border and femoral head of P5 **M)** kyphosis of P5 **N)** posterior scalloping and inferior beaking of vertebral bodies of P6 **O)** rounded iliac wings, inferior tapering of the ilea, coxa valga of P6 **P)** bullet-shaped metacarpal bones of P6 **Q)** Oar-shaped ribs of P6

C-reactive protein levels and response to nonsteroidal anti-inflammatory drugs are absent (11,12).

In the presence of findings of skeletal deformity, and during the clinical examination, some accompanying clinical signs, such as macrocephaly, corneal clouding, and/or umbilical hernia can provide clues for a diagnosis of MPS. In addition, hearing impairment, recurrent respiratory tract and middle ear infections, cardiac abnormalities, and/or development delay are other extra-skeletal manifestations that should raise suspicion of storage disorders like MPS (13,14,15).

Patient I presented with short stature and facial dysmorphism may be supposed to be an attenuated form of MPS. Although J-shaped sella and oar-shaped ribs were observed, beaking of vertebral bodies that is strongly expected in MPS patients was absent. In Patient IV, vertebral deformities were also not typical for MPS as they resembled the biconcave vertebral bodies observed in Patient I. Patient IV was provisionally diagnosed as SD because of the lack of the typical short stature with short trunk and beaking of vertebral bodies, but surprisingly was finally diagnosed as MPS IV. It should be noted that imaging findings may be mild or atypical in early childhood or in attenuated form of MPS that have a later onset with slower progression (16). Patient II also exhibited flattened vertebral bodies, with a similar appearance of the vertebral bodies seen in Patient IV. Therefore, considering those atypical or mild presentations it is not surprising that in several studies it has been showed that about half of the MPS IV patients were misdiagnosed with spondyloepiphyseal dysplasia (SED), based on radiographic interpretations (13).

It is important to accurately interpret vertebral abnormalities to distinguish between the two entities, MPS and SD. The presence of superior notched vertebra in addition to scoliosis and/or kyphosis is a common finding in SED while platyspondyly or humping of vertebral bodies is not consistently present (13). Moreover, one of the most significant findings on spinal radiograph in MPS is beaking of vertebrae and in SD are tongue-like projections, for example in pseudo achondroplasia. Although these features may appear similar, the thicker and wider shape of tongue-like projection is a helpful distinction (17,18). In addition to the spinal deformities, the deposition of glycosaminoglycans in the soft tissues contributes to cervical cord compression that occurs in MPS rather than SD. However, it should be noted that the incidence of myelopathy caused by atlantoaxial subluxation is present in nearly one third of patients with SED congenita (19,20).

The pelvic radiograph may also be useful in revealing distinctive radiological findings for SD and MPS. The square ilium is commonly associated with the achondroplasia group or Ellis-van Creveld syndrome, but is not usually present in MPS. The pelvic

pattern in MPS is one of hypoplasia of the lower half of the ilium, which narrows and tapers inferiorly (21,22,23). Although the pelvic manifestations of MPS IV, SD and atypical phenotypes may overlap, distinguishing and features found only in MPS IV of all the MPS subtypes, such as genu valgum and joint laxity, may also contribute to earlier and correct diagnosis (4).

Patients V and VI are typical presentations of MPS IV and MPS I, respectively. Radiological findings are evident, even in infancy. However, early onset skeletal deformities in SD, such as ovoid configuration and beaking of vertebral bodies, as observed in Patient III, may mimic MPS. The central tongue of ossified bone extends anteriorly from the vertebral body in MPS IV patients. With a little distinction from MPS IV, MPS I is associated with inferior beaking of vertebral body. Another striking feature to help to identify the MPS subtype is that in MPS I, the L1 and L2 hypoplastic vertebral bodies commonly have posterior scalloping with dorsal gibbus, while in MPS IV platyspondyly and central beaking is widespread in the thoracolumbar vertebral bodies, as seen in Patient V (13,24). Furthermore, pelvic radiographic investigation may also assist in subtyping of MPS subtypes. In a patient with MPS IV, epiphyseal dysplasia of the caput femoris would accompany the tapered ilium, unlike in MPS I (4).

Radiological examination following by an enzyme activity assays will establish the initial diagnostic workflow and provide data to perform targeted molecular genetic tests. Although molecular genetic tests are essential tools for diagnosis, clinical confirmation remains necessary in some SDs because of an autosomal dominant inheritance pattern and variants of unknown significance.

Study Limitations

This was a retrospective study and so different radiological or biochemical analyses were not performed that might be requested for the differential diagnosis of patients.

Conclusion

Awareness of comprehensive clinical and radiological evaluation that guide an appropriate approach for distinguishing between MPS and SD is essential for establishing an accurate and timely diagnosis. This report has presented a summary of such distinguishing features which it is hoped will facilitate diagnosis by highlighting clues present at clinical presentations and on radiological imaging.

Ethics

Ethics Committee Approval: Ethical approval was granted by the Ethics Committee of Gazi University (approval no.: 12, date: 09.07.2024).

Informed Consent: Informed consent forms were obtained from patients or their parents.

Footnotes

Authorship Contributions

Surgical and Medical Practices: Ayşe Akyüz, Hakan Atalar, Kübra Çilesiz, Aslı İnci, Concept: Fatih Ezgü, Design: Ayşe Akyüz, Fatih Ezgü, Data Collection or Processing: Ayşe Akyüz, Hakan Atalar, Kübra Çilesiz, Aslı İnci, Analysis or Interpretation: Ayşe Akyüz, İlyas Okur, Leyla Tümer, Fatih Ezgü, Literature Search: Ayşe Akyüz, İlyas Okur, Leyla Tümer, Fatih Ezgü, Writing: Ayşe Akyüz.

Financial Disclosure: There is no specific funding related to this research.

References

1. Neufeld EU, Muenzer J. The mucopolysaccharidoses. In: Scriver CR, ed. The metabolic and molecular bases of inherited disease. New York: McGraw-Hill, 2001:342152.
2. Muenzer J. Overview of the mucopolysaccharidoses. *Rheumatology (Oxford)*. 2011;50(Suppl 5):v12.
3. Mortier GR, Cohn DH, Cormier-Daire V, Hall C, Krakow D, Mundlos S, Nishimura G, Robertson S, Sangiorgi L, Savarirayan R, Sillence D, Superti-Furga A, Unger S, Warman ML. Nosology and classification of genetic skeletal disorders: 2019 revision. *Am J Med Genet A*. 2019;179:2393-2419. Epub 2019 Oct 21
4. Bhattacharya K, Balasubramaniam S, Choy YS, Fietz M, Fu A, Jin DK, Kim OH, Kosuga M, Kwun YH, Inwood A, Lin HY, McGill J, Mendelsohn NJ, Okuyama T, Samion H, Tan A, Tanaka A, Thamkunanon V, Toh TH, Yang AD, Lin SP. Overcoming the barriers to diagnosis of Morquio A syndrome. *Orphanet J Rare Dis*. 2014;9:192.
5. MacCarrick G, Aradhya S, Bailey M, Chu D, Hunt A, Izzo E, Krakow D, Mackenzie W, Poll S, Raggio C, Shediak R, White KK, McLaughlin HM, Seratti G. Clinical utility of comprehensive gene panel testing for common and rare causes of skeletal dysplasia and other skeletal disorders: results from the largest cohort to date. *Am J Med Genet A*. 2024;194:e63646. Epub 2024 May 3
6. Muenzer J. The mucopolysaccharidoses: a heterogeneous group of disorders with variable pediatric presentations. *J Pediatr*. 2004;144(5 Suppl):27-34.
7. Seaver LH, Irons M; American College of Medical Genetics (ACMG) Professional Practice and Guidelines Committee. ACMG practice guideline: genetic evaluation of short stature. *Genet Med*. 2009;11:465-470.
8. Collett-Solberg PF, Ambler G, Backeljauw PF, Bidlingmaier M, Biller BMK, Boguszewski MCS, Cheung PT, Choong CSY, Cohen LE, Cohen P, Dauber A, Deal CL, Gong C, Hasegawa Y, Hoffman AR, Hofman PL, Horikawa R, Jorge AAL, Juul A, Kamenický P, Khadiilkar V, Kopchick JJ, Kriström B, Lopes MLA, Luo X, Miller BS, Misra M, Netchine I, Radovick S, Ranke MB, Rogol AD, Rosenfeld RG, Saenger P, Wit JM, Woelfle J. Diagnosis, genetics, and therapy of short stature in children: A Growth Hormone Research Society international perspective. *Horm Res Paediatr*. 2019;92:1-14. Epub 2019 Sep 12
9. Dauber A, Rosenfeld RG, Hirschhorn JN. Genetic evaluation of short stature. *J Clin Endocrinol Metab*. 2014;99:3080-3092. Epub 2014 Jun 10
10. Vijay S, Wraith JE. Clinical presentation and follow-up of patients with the attenuated phenotype of mucopolysaccharidosis type I. *Acta Paediatr*. 2005;94:872-877.
11. Cimaz R, Coppa GV, Koné-Paut I, Link B, Pastores GM, Elorduy MR, Spencer C, Thorne C, Wulffraat N, Manger B. Joint contractures in the absence of inflammation may indicate mucopolysaccharidosis. *Pediatr Rheumatol Online J*. 2009;7:18.
12. Cimaz R, Vijay S, Haase C, Coppa GV, Bruni S, Wraith E, Guffon N. Attenuated type I mucopolysaccharidosis in the differential diagnosis of juvenile idiopathic arthritis: a series of 13 patients with Scheie syndrome. *Clin Exp Rheumatol*. 2006;24:196-202.
13. Lachman RS, Burton BK, Clarke LA, Hoffinger S, Ikegawa S, Jin DK, Kano H, Kim OH, Lampe C, Mendelsohn NJ, Shediak R, Tanpaiboon P, White KK. Mucopolysaccharidosis IVA (Morquio A syndrome) and VI (Maroteaux-Lamy syndrome): under-recognized and challenging to diagnose. *Skeletal Radiol*. 2014;43:359-369. Epub 2014 Jan 4
14. Montañó AM, Tomatsu S, Gottesman GS, Smith M, Orii T. International Morquio A registry: clinical manifestation and natural course of Morquio A disease. *J Inher Metab Dis*. 2007;30:165-174. Epub 2007 Mar 8
15. Hendriksz CJ, Al-Jawad M, Berger KI, Hawley SM, Lawrence R, Mc Ardle C, Summers CG, Wright E, Braunlin E. Clinical overview and treatment options for non-skeletal manifestations of mucopolysaccharidosis type IVA. *J Inher Metab Dis*. 2013;36(Suppl 2):309-322. Epub 2012 Feb 23
16. Watson SG, Calder AD, Offiah AC, Negus S. A review of imaging protocols for suspected skeletal dysplasia and a proposal for standardisation. *Pediatr Radiol*. 2015;45:1733-1737. Epub 2015 Jun 17
17. Weiner DS, Guirguis J, Makowski M, Testa S, Shauer L, Morgan D. Orthopaedic manifestations of pseudoachondroplasia. *J Child Orthop*. 2019;13:409-416.
18. Gabra P, Jana M, Naranje P, Gupta N, Kabra M, Gupta AK, Yadav R. Spine radiograph in dysplasias: a pictorial essay. *Indian J Radiol Imaging*. 2020;30:436-447. Epub 2021 Jan 13
19. Miyoshi K, Nakamura K, Haga N, Mikami Y. Surgical treatment for atlantoaxial subluxation with myelopathy in spondyloepiphyseal dysplasia congenita. *Spine (Phila Pa 1976)*. 2004;29:E488-E491.
20. Ransford AO, Crockard HA, Stevens JM, Modagheh S. Occipito-atlanto-axial fusion in Morquio-Brailesford syndrome. A ten-year experience. *J Bone Joint Surg Br*. 1996;78:307-313.
21. Kozłowski K, John E, Masel J, Muralinath S, Vijayalakshmi G. Case report: neonatal platyspondylic dwarfism--a new form. *Br J Radiol*. 1995;68:1254-1256.
22. Lehman TJ, Miller N, Norquist B, Underhill L, Keutzer J. Diagnosis of the mucopolysaccharidoses. *Rheumatology (Oxford)*. 2011;50(Suppl 5):V41-48.
23. Gajarajulu V, Natarajan B, Muralinath S. The radiograph of the pelvis as a window to skeletal dysplasias. *Indian J Pediatr*. 2016;83:543-552. Epub 2016 Jan 29
24. Lee NH, Cho SY, Maeng SH, Jeon TY, Sohn YB, Kim SJ, Park HD, Jin DK. Clinical, radiologic, and genetic features of Korean patients with mucopolysaccharidosis IVA. *Korean J Pediatr*. 2012;55:430-437. Epub 2012 Nov 23 Erratum in: *Korean J Pediatr*. 2013;56:143.